

Thrombosis of an External Jugular Vein Aneurysm: An Uncommon Cause of Cervical Mass

C. Doutrelon^{1*}, A. Crambert², C. Holmann³, M-N. De La Lance³, M. Aletti¹⁻⁴


¹Department of Internal Medicine and Rheumatology, Percy Military Training Hospital, France

²Department of ENT Surgery Department, Percy Military Training Hospital, France

³Department of Radiology, Percy Military Training Hospital, France

⁴Val-de-Grâce Academy, France

*Correspondence: C. Doutrelon, Department of Internal Medicine and Rheumatology, Percy Military Training Hospital, Avenue Henri Barbusse, 92140 Clamart, France

 caro0313@gmail.com

Radiology Case. 2024 December; 18(12):47-52 :: DOI: 10.3941/jrcr.5525

Authors' Contributions

Caroline Doutrelon: patient management, writing of the article
 Anna Crambert: patient management, correction of the article
 Charlotte Holmann: patient management, correction of the article
 Marie-Noelle De La Lance: patient management, correction of the article
 Marc Aletti: correction of the article

Conflict of Interest / Disclosures

No conflicts of interest

Ethical Statement / Human And Animal Rights

If reporting experiments on human or animal subjects, please indicate if ethical standards followed the responsible committee on human experimentation (institutional and national) and with the Helsinki Declaration of 1975, as revised in 2000 (5).

ABSTRACT

Introduction: Venous aneurysms are rare vascular anomalies, particularly external jugular vein (EJV) aneurysms. Their nonspecific clinical features complicate diagnosis, and thrombosis within these aneurysms, though uncommon, heightens the risk of serious complications like thrombus extension and pulmonary embolism.

Case Report: We present a 62-year-old hypertensive female with a 12-month history of a fluctuating, painless neck mass that increased in size during Valsalva maneuvers. Recently, the mass became persistent and painful, prompting medical evaluation. Examination revealed a firm, mobile, slightly tender mass on the left neck. Imaging, including CT and venous Doppler ultrasound, indicated an indeterminate lesion. Surgical cervicotomy and vein ligation confirmed a thrombosed EJV aneurysm. Postoperatively, anticoagulation led to complete recanalization, with no recurrence at six months.

Discussion: Thrombosed venous aneurysms pose a diagnostic challenge due to their rarity and nonspecific presentation. This case highlights the need for early surgical intervention and anticoagulation to avert complications.

Conclusion: This case emphasizes the importance of considering thrombosed EJV aneurysms in cervical mass differentials, as prompt diagnosis and management can significantly enhance patient outcomes.

CASE REPORT

BACKGROUND

External jugular vein (EJV) aneurysms and their complications are rare vascular abnormalities that can present

diagnostic and therapeutic challenges. While venous aneurysms are more commonly reported in deep veins, isolated aneurysms of the EJV are uncommon and often asymptomatic. However, thrombosis within these aneurysms can lead to significant

complications, including embolism and venous obstruction, necessitating timely diagnosis and management.

The clinical presentation of an EJV thrombosed aneurysm can mimic other cervical masses, such as lymphadenopathy, tumors, or vascular malformations, making imaging modalities such as Doppler ultrasound, CT angiography, and MRI essential for accurate diagnosis. The etiology of EJV aneurysms remains unclear but may involve congenital weakness of the venous wall, trauma, or degenerative changes. In some cases, spontaneous dissection or rupture of the vein can lead to acute thrombus formation, as observed in our case.

Surgical intervention remains the mainstay treatment for symptomatic or complicated cases, particularly when there is a risk of embolization or progressive thrombosis. In this report, we present a rare case of a thrombosed external jugular vein aneurysm requiring surgical management, discuss its diagnostic and therapeutic implications, and review relevant literature on this unusual condition.

CASE REPORT

We report the case of a 62-year-old hypertensive female patient who was treated for a thrombosed external jugular vein aneurysm. She had no personal or family history of aneurysms or venous thromboembolic disease.

The patient presented with a fluctuating mass at the base of the neck, in the vertebrobasilar zone on the left side, which had been present for 12 months and increased in size during Valsalva maneuvers, without prompting her to seek medical attention. Recently, the cervical mass had become persistent and painful.

Clinically, the mass was firm, mobile, and slightly tender to palpation, located at the base of the neck, lateralized to the left side. The patient did not report any recent trauma or catheter placement. The remainder of the clinical examination was unremarkable, with no palpable lymphadenopathy. The biological workup revealed no significant abnormalities, including the absence of an inflammatory syndrome.

A cervical CT scan revealed a tissue-like lesion measuring 30 mm in the left supraclavicular region, displacing the external jugular vein (Figure 1). The lesion initially suggested lymphadenopathy, but the CT appearance was uncertain. A subsequent venous Doppler ultrasound revealed a superficial, 30 mm tissue-like mass that was difficult to characterize. The mass displaced the external jugular vein but did not appear to involve surrounding structures.

The diagnosis was ultimately confirmed through surgery with a cervicotomy at the lesion site and ligation of the vein on both sides of the thrombus. The surgery involved a left supraclavicular incision to expose the external jugular vein. Dissection was carried out carefully to isolate the vein, revealing a thrombus within the vessel. The thrombus was

removed through a longitudinal venotomy, and primary closure of the vein was performed (Figure 2). The decision to avoid vein resection was based on the absence of any major wall damage, as confirmed intraoperatively. Histopathological analysis revealed an intrajugular thrombus associated with alterations in the venous wall, indicative of an underlying aneurysm. A postoperative Doppler ultrasound showed persistent thrombosis of the left external jugular vein.

The patient was treated with curative anticoagulation therapy using Rivaroxaban, 15 mg twice daily for 21 days, followed by 20 mg once daily for a total of 3 months. The clinical course was favorable, with complete recanalization of the external jugular vein observed on follow-up Doppler ultrasound. The patient had no recurrence after 6 months of follow-up.

DISCUSSION

Venous aneurysms are rare vascular anomalies defined as localized dilations of veins, accounting for less than 1% of all aneurysms in the general population [1]. These conditions are primarily congenital but may also arise from trauma, infections, or structural alterations of the vascular wall [1]. While the most common locations for venous aneurysms include the lower limbs, internal jugular veins, and veins of the upper limbs, aneurysms of the external jugular vein (EJV) are particularly uncommon, with only a limited number of cases reported in the literature [2-4]. EJV aneurysms often present diagnostic challenges due to their nonspecific clinical features [5]. The typical presentation involves fluctuating cervical masses that may increase in size during Valsalva maneuvers, sometimes persisting for several months [6]. The clinical examination typically reveals a painful cervical mass, which can easily be confused with other conditions such as lymphadenopathy or neoplastic masses [6, 7]. In the case presented, the patient experienced these symptoms for 12 months prior to seeking medical attention. Initial imaging, including cervicothoracoabdominopelvic CT scans, may yield nonspecific results, suggesting indeterminate tissue-like lesions, while venous Doppler ultrasound may fail to adequately characterize the mass.

In our case, the search for a triggering factor was inconclusive. Spontaneous external jugular vein aneurysms are indeed rare and are usually congenital or secondary to trauma, infections, or structural changes in the vascular wall, often resulting from venous catheter placement [5].

The management of thrombosis associated with venous aneurysms is complex, primarily due to the increased risk of severe complications such as thrombus extension and pulmonary embolism [8]. The management of such cases remains debated between surgical and medical approaches, including curative anticoagulation therapy, due to the lack of consensus in the literature arising from the rarity of reported cases [4]. In our case, surgical management was favored due to the painful and persistent nature of the mass, the absence of risk for sequelae, and the need for diagnostic confirmation. Surgery allowed for the confirmation of a thrombosed aneurysm. Postoperatively,

anticoagulant therapy was effective in preventing thrombus propagation and promoting the recanalization of the external jugular vein in its proximal portion.

The medical literature on thrombosed external jugular vein aneurysms is limited, posing challenges in diagnosis and management.

The case of a thrombosed external jugular vein aneurysm presented here highlights the rarity and diagnostic complexity of this condition. The nonspecific clinical presentation and inconclusive initial imaging emphasize the need for a thorough diagnostic approach. Management, including surgical intervention followed by curative anticoagulation, resulted in a favorable outcome, with complete recanalization of the proximal external jugular vein and no recurrence after six months of follow-up.

TEACHING POINT

This case underscores the importance of considering thrombosed venous aneurysms in the differential diagnosis of cervical masses and demonstrates that, although rare, these conditions require prompt and appropriate management to prevent complications.

QUESTIONS

Question 1:

What is a venous aneurysm defined as?

- A) A localized dilation of a vein (applies)
- B) A congenital vascular malformation (applies)
- C) A neoplastic mass
- D) An inflammatory condition
- E) A structural alteration of the artery

Explanation:

A venous aneurysm is specifically defined as a localized dilation of a vein, making option A correct. While they are often congenital, they can also arise due to structural alterations, making option B applicable as well. Options C, D, and E are incorrect as they do not define a venous aneurysm. This is supported by the sentence: "A venous aneurysm is defined as a localized dilation of a vein and is a rare vascular anomaly..."

Question 2:

Which factors can contribute to the development of an external jugular vein aneurysm?

- A) Congenital factors (applies)
- B) Trauma (applies)
- C) Infections (applies)
- D) Surgical interventions
- E) Venous catheter placement (applies)

Explanation:

External jugular vein aneurysms can arise from congenital factors, trauma, infections, and venous catheter placement. Therefore, options A, B, C, and E are all correct. Option D is not specifically mentioned as a contributing factor in this context.

This is supported by the statement: "They are typically either congenital or secondary to trauma, infections, or structural alterations of the vascular wall, often due to venous catheter placement"

Question 3:

What are common clinical presentations of external jugular vein aneurysms?

- A) Fluctuating cervical masses (applies)
- B) Persistent neck pain (applies)
- C) Rapid weight loss
- D) Increases in size during Valsalva maneuvers (applies)
- E) Fever

Explanation:

External jugular vein aneurysms typically present as fluctuating cervical masses that may increase in size during Valsalva maneuvers, making options A and D correct. Persistent neck pain can occur but is less characteristic, hence option B is also applicable. Options C and E are incorrect, as they are not standard presentations associated with these aneurysms. This is referenced in the statement: "The clinical presentation appears to be stereotypical, often manifesting as fluctuating cervical masses that increase in size during Valsalva maneuvers".

Question 4:

What are the complications associated with thrombosis in venous aneurysms?

- A) Thrombus extension (applies)
- B) Pulmonary embolism (applies)
- C) Increased risk of infection
- D) Hemorrhage
- E) Chronic pain

Explanation:

Thrombosis in venous aneurysms increases the risk of thrombus extension and pulmonary embolism, making options A and B correct. Options C, D, and E are not explicitly linked to the complications of thrombosis in the context of venous aneurysms as described in the manuscript. This is highlighted in the sentence: "Although rare, thrombosis associated with a venous aneurysm complicates management due to the increased risk of complications, particularly thrombus extension and pulmonary embolism".

Question 5:

What management strategies are discussed for thrombosed external jugular vein aneurysms?

- A) Surgical intervention (applies)
- B) Anticoagulation therapy (applies)
- C) Observation only
- D) Radiation therapy
- E) Antibiotic therapy

Explanation:

The management of thrombosed external jugular vein aneurysms can include surgical intervention and anticoagulation therapy, making options A and B correct. Options C, D, and E are not supported as appropriate strategies within the context

of the manuscript. This is indicated by the statement: "In our case, surgical management was favored... Postoperatively, anticoagulant therapy was effective".

REFERENCES

1. Ekim H, Kutay V, Tuncer M, Gultekin U. Management of primary venous aneurysms. *Saudi Med J*. 2004; 25(3): 303-307. PMID: 15048166.
2. Hopsu E, Pitkäranta A. Jugular vein aneurysm or phlebectasia. *Am J Surg*. 2004; 188(5): 622. PMID: 15546584.
3. Iqbal K. A True Thrombosed External Jugular Vein Aneurysm Presenting as a Cervical Mass: A Case Report and Literature Review. *Cureus*. 2022; 14(6): e25757. PMID: 35812646.
4. Teter KA, Maldonado TM, Adelman MA. A systematic review of venous aneurysms by anatomic location. *J Vasc Surg Venous Lymphat Disord*. 2018; 6(3): 408-413. PMID: 29661366.
5. Nucera M, Meuli L, Janka H, Schindewolf M, Schmidli J, Makaloski V. Comprehensive review with pooled analysis on external and internal jugular vein aneurysm. *J Vasc Surg Venous Lymphat Disord*. 2022; 10(3): 778-785.e2. PMID: 34634519.
6. Thakur UK, Savlania A, Naik AL, Singh C, Chatterjee D, Gorski U. Clinical profile and management of external jugular vein aneurysms. *Phlebology*. 2021; 36(5): 401-406. PMID: 33251950.
7. Kaygin MA, Erkut B, Ceviz M. External Jugular Vein Aneurysm as a Rare Cause of Neck Swelling. *Ann Saudi Med*. 2008; 28(1): 62. PMID: 18299648.
8. Muñoz FJ, Mismetti P, Poggio R, et al. Clinical Outcome of Patients With Upper-Extremity Deep Vein Thrombosis: Results From the RIETE Registry. *Chest*. 2008; 133(1): 143-148. PMID: 17925416.

FIGURES

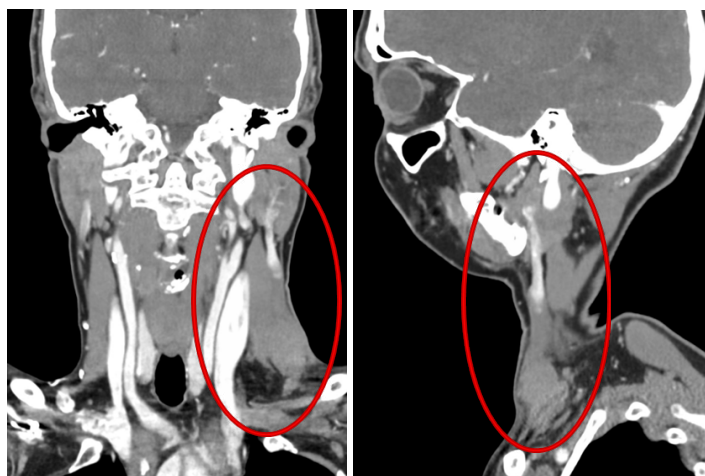


Figure 1: 62-year-old woman presenting with a cervical mass : cervico-thoracic CT scan was performed with 70 cc of iodinated contrast (iomeron), acquired during the venous phase in axial, coronal, and sagittal planes.

A sagittal cervical CT scan with contrast enhancement revealed a left supraclavicular lesion. The imaging demonstrated a tissue-like mass measuring 30 mm in diameter, displacing the external jugular vein. This mass was characterized as isolated superficial left cervical adenopathy located on the superficial posterior aspect of the left sternocleidomastoid muscle. The mass measured 30 mm and displaced the external jugular vein anteriorly. No necrotic components were observed, and no other adenopathy was detected. There were no lesions in the pharynx or larynx. The internal jugular veins and supra-aortic trunks showed no stenosis, but there was mild infiltration of the carotid bulbs

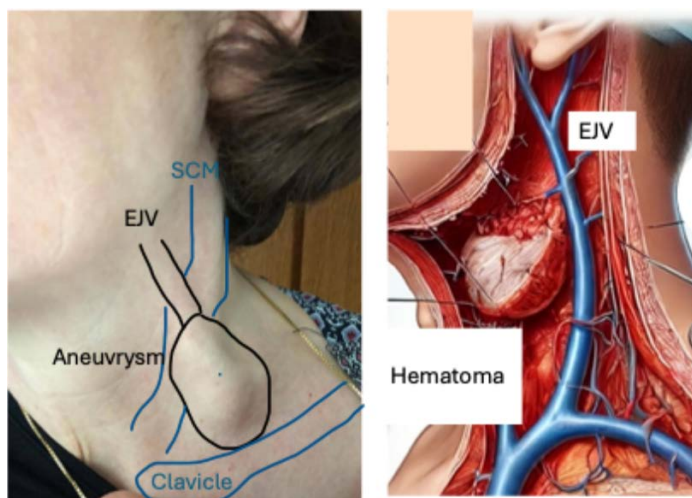


Figure 2: Representation of the surgical procedure showing the anatomical lesions, the supraclavicular approach to expose the external jugular vein, the evacuation of the hematoma, and the ligation of the vein

A – Gross examination of the neck showing swelling in the left supraclavicular region; SCM: sternocleidomastoid muscle, EJV: external jugular vein. B – Dissection isolating the external jugular vein, revealing a thrombus within the vessel. The thrombus was removed via a longitudinal venotomy, followed by primary closure of the vein.

SUMMARY TABLE

Parameter	Details
Etiology	Likely related to venous wall weakness
Incidence	Rare; <1% of all venous aneurysms
Gender ratio	No clear gender predilection
Age predilection	No clear age predilection
Clinical presentation	Painless, soft, cervical mass, enlarging with Valsalva
Diagnostic Techniques	Ultrasound Doppler, CT with contrast
Management	Surgical resection, anticoagulation therapy
Prognosis	Favorable evolution with a low risk of recurrence.

KEYWORDS

Venous aneurysm, external jugular vein, thrombosis, cervical mass, anticoagulation therapy

Online access

This publication is online available at:
www.radiologycases.com/index.php/radiologycases/article/view/5525

Peer discussion

Discuss this manuscript in our protected discussion forum at:
www.radiopolis.com/forums/JRCR

Interactivity

This publication is available as an interactive article with scroll, window/level, magnify and more features.
Available online at www.RadiologyCases.com

Published by EduRad



www.EduRad.org