

When Radiologists Plays Detective: Uncovering surgical foreign body in the Abdomen

Marco De Chiara^{1,2}, Dario Grimaldi³, Maria Rita Cristiano¹, Francesca Grassi¹, Nicoletta Giordano¹, Pasquale Parrella¹, Diego Sandro Giordano¹, Alfonso Reginelli¹, Maria Paola Belfiore^{1*}

¹Department of Precision Medicine, University of Campania "L. Vanvitelli", Italy

²Department of radiology, medical-surgical hospital "Villa dei Fiori", Italy

³General and Emergency Radiology Department, "Antonio Cardarelli" Hospital, Italy

*Correspondence: Maria Paola Belfiore; Department of Radiology, university of Campania "L. Vanvitelli", Piazza Luigi Miraglia, 5, Naples, Italy

✉ mariapaola.belfiore@unicampania.it

Radiology Case. 2024 Mar; 18(3):33-37 :: DOI: 10.3941/jrcr.v18i3.5288

ABSTRACT

Despite careful adherence to precautionary protocols, abdominal foreign bodies may still be discovered after surgery on occasion, posing significant risks for both the patient and the surgical team. While symptoms may occasionally manifest rapidly, more commonly, they tend to be chronic and lack alternative explanations. In the presented case, a patient was identified with a metallic foreign body years following abdominal surgery. Foreign bodies typically necessitate surgical intervention, prioritizing preventive measures during surgical procedures to actively minimize the occurrence of such incidents.

CASE REPORT

INTRODUCTION

Below is reported the clinical case of a 25-year-old male who arrived at our emergency room with enduring pain persisting for approximately 24 months, focused on the left lumbar and corresponding inguinal regions. The patient's history revealed gastric banding performed four years prior, followed by a revision intervention a few months later due to a port-a-cath complication, resulting in sudden weight loss; no follow-up assessment was conducted after discharge. No other significant findings arose during the patient history review. Vital signs including blood pressure, heart rate, respiratory rate, and body temperature were within normal ranges. Upon clinical examination, heightened resistance was noted in the left lumbar and inguinal regions, particularly near the surgical scar, with palpation eliciting pain. Blood tests showed no significant alterations. The patient was then directed to the radiology ward for an abdominal X-ray (Figure 1). Erect anteroposterior and lateral views of the abdomen revealed radiographs displaying a surgical tool, likely a forceps or klemmer, in the left abdomen.

Recognizing the need for surgical intervention, we opted for further diagnostic investigation with an abdominal CT (Figure 2) The CT scan unequivocally confirmed the presence of a surgical instrument in the prefascial subcutaneous fat layer in the left hemiabdominal region. No significant changes in the surrounding area were observed, and there were no vascular or peritoneal complications. A single enlarged node, part of the external iliac lymph nodes group, was identified (Figure 3).

Given its proximity to the foreign body area, we interpreted this anomaly as a normal inflammatory response to the nearby foreign body; therefore, no additional investigation was pursued. Once the surgeons were alerted, the patient was promptly transferred to the surgical ward. The laparotomic removal of the klemmer was performed the following day without issues, and the patient was subsequently hospitalized (Figure 4,5). No further complications occurred, leading to the patient's discharge after seven days.

DISCUSSION

Encountering foreign bodies during radiological examinations of the pelvis and abdomen is not uncommon (1/1000) [1]. Most often, these objects are associated with prior surgeries or interventional medical procedures [2]. Given the challenge of pinpointing the exact introduction moment into the patient's abdomen through anamnestic evaluation alone, radiological exams become crucial for characterizing their nature and, more importantly, determining their precise location [3]. It is imperative to differentiate between intraluminal objects within the gastrointestinal tract and extraluminal objects in the peritoneal cavity, aiding surgeons in appropriate patient management. Instruments and drains left in the abdomen post-surgery can lead to complications such as adhesion, bowel obstruction, abscesses, erosion of the gastrointestinal tract, intussusception and granulomas [4,5]. Symptoms may not manifest for months or even years, complicating the clinical picture and challenging the diagnostic process [6]. Among various tools, gauzes and hemostatic tampons appear most

frequently in the abdominal cavity after laparotomic surgery, despite precautionary measures [7,8]. Incidents of this nature are fueling an escalating number of serious legal discussions and pose significant dangers for both the patient and the surgical team [9].

Early detection of the foreign body is pivotal to prevent severe complications jeopardizing the patient's health and exposing the entire surgical team to significant legal issues. Strict adherence to safety protocols is crucial to preclude such occurrences, even in urgent and chaotic situations. The responsibility for following these protocols should be emphasized and assigned to the operating surgeon [10]. Moreover, in the event of a patient experiencing acute or chronic abdominal pain after a surgical procedure, a radiological evaluation is deemed mandatory and non-negotiable.

TEACHING POINTT

Despite precautionary measures, there is a persistent risk of post-surgery abdominal foreign bodies, necessitating surgical intervention. The crucial role of preventive protocols during surgery and the significance of timely radiological evaluations underscore the need for heightened awareness in addressing complications and legal implications.

AUTHORS' CONTRIBUTIONS

Marco De Chiara: Writing the initial drafting of the manuscript and subsequent editing.

Dario Grimaldi: Conceptualization of the idea and defining the paper's objectives.

Alfonso Reginelli: Revising content, structure and addressing feedback.

Maria Paola Belfiore: Guidance and supervision.

HUMAN AND ANIMAL RIGHTS

Ethical standards followed the responsible committee on human experimentation (institutional and national) and the Helsinki Declaration of 1975, as revised in 2000.

REFERENCES

1. Birolini DV, Rasslan S, Utiyama EM. Retenção inadvertida de corpos estranhos após intervenções cirúrgicas. Análise de 4547 casos. *Revista do Colegio Brasileiro de Cirurgioes*. 2016; 43(1): 12–7.
2. Gayer G, Petrovitch I, Jeffrey RB. Foreign objects encountered in the abdominal cavity at CT. *Radiographics*. 2011; 31(2): 409–428. PMID: 21415187.
3. Nastoulis E, Karakasi MV, Alexandri M, Thomaidis V, Fiska A, Pavlidis P. Foreign bodies in the abdominal area: review of the literature. *Acta Medica (Hradec Kralove)*. 2019; 62(3): 85-93. PMID: 31663500.
4. Somma F, Faggian A, Serra N, et al. Bowel intussusceptions in adults: the role of imaging. *Radiol Med*. 2015; 120(1): 105-117. PMID: 25115295.
5. Reginelli A, Mandato Y, Solazzo A, Berritto D, Iacobellis F, Grassi R. Errors in the radiological evaluation of the alimentary tract: part II. *Semin Ultrasound CT MR*. 2012; 33(4): 308-317. PMID: 22824121.
6. Klein J, Farman J, Burrell M, Demeter E, Frosina C. The forgotten surgical foreign body. *Gastrointest Radiol*. 1988; 13(1): 173–176. PMID: 3360252.
7. Gayer G, Lubner MG, Bhalla S, Pickhardt PJ. Imaging of abdominal and pelvic surgical and postprocedural foreign bodies. *Radiol Clin North Am*. 2014; 52(5): 991-1027. PMID: 25173655.
8. Modrzejewski A, Kaźmierczak KM, Kowalik K, Grochal I. "Surgical items retained in the abdominal cavity in diagnostic imaging tests: a series of 10 cases and literature review." *Pol J Radiol*. 2023; 5:88: e264-e269. PMID: 37404550.
9. Hariharan D, Lobo DN. Retained surgical sponges, needles and instruments. *Ann R Coll Surg Engl*. 2013; 95(2): 87–92. PMID: 23484986.

FIGURES

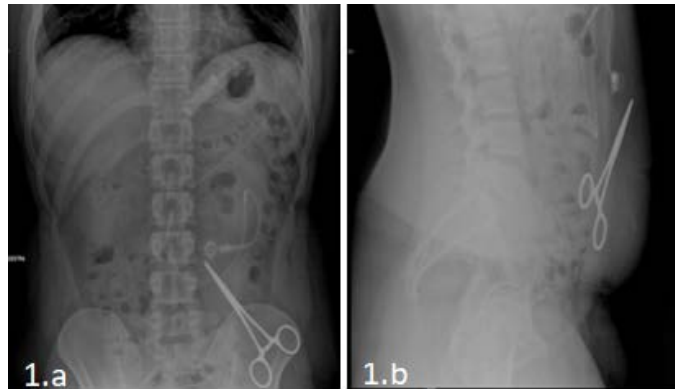


Figure 1: Plain X-ray of the abdomen in orthostatic PA (1.a) and LL (1.b) view demonstrates a metallic foreign body in left flank/left iliac fossa.

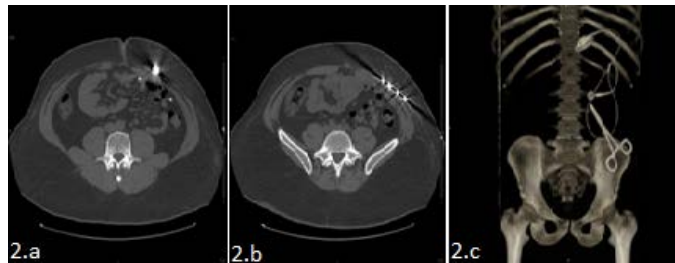


Figure 2: Axial non-contrast enhanced CT of the abdomen confirms a metallic foreign body in the left flank/iliac fossa (2.a; 2.b). 3D reconstruction (2.c) is provided for better understanding.

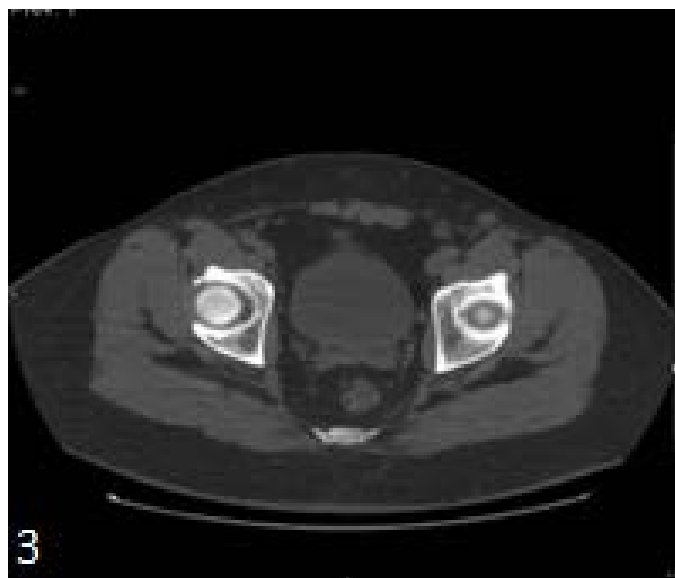


Figure 3: Axial non-contrast enhanced CT of the abdomen demonstrates an enlarged lymph node in the left inguinal region.

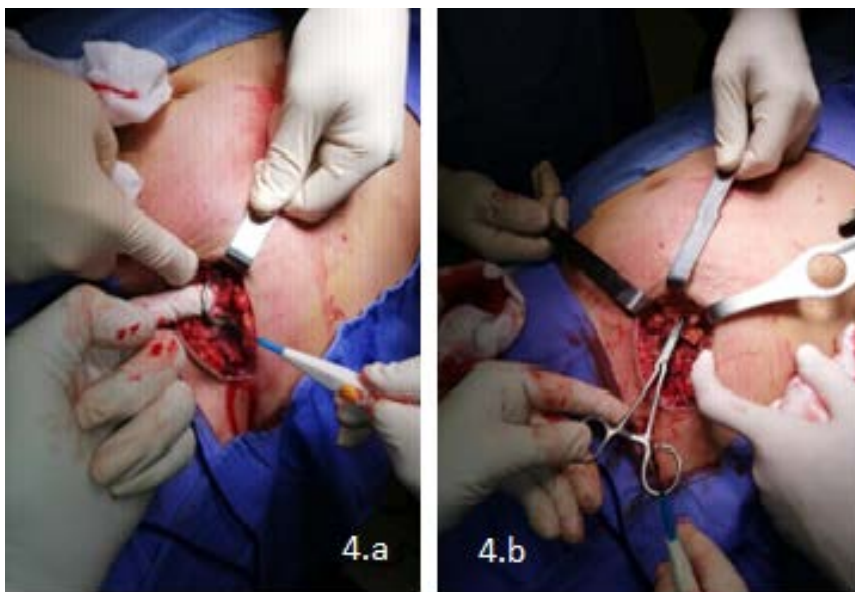


Figure 4: Surgical extraction of the foreign body seen on radiological assessment.

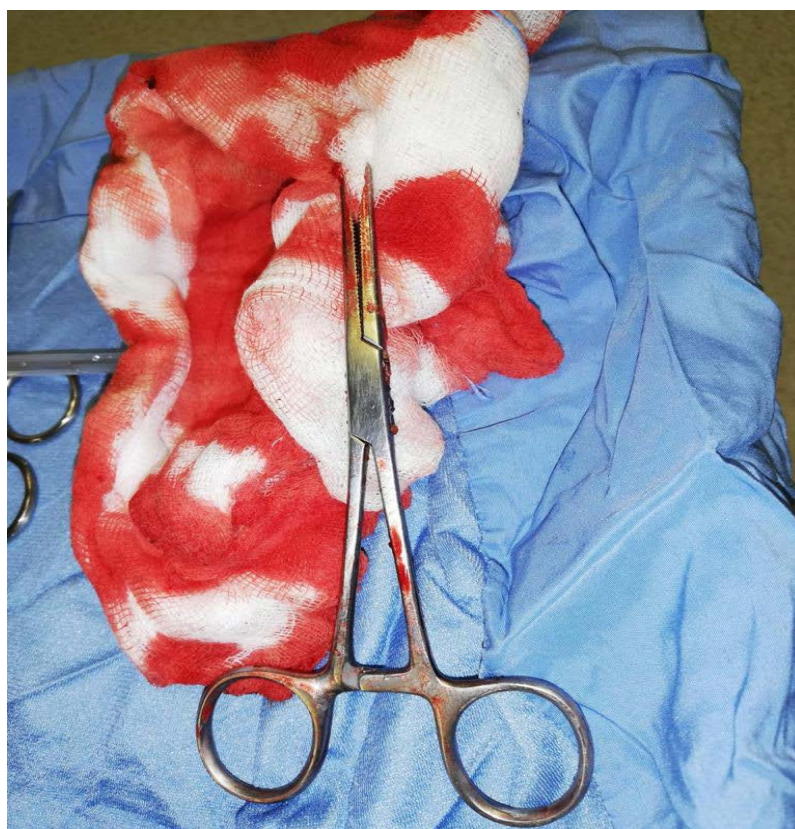

Figure 5: Foreign body (Klemmer caliper) removed from the patient's abdomen.

KEYWORDS

Foreign bodies; Abdominal surgery; Surgical complication; CT; X-ray

Online access

This publication is online available at:

www.radiologycases.com/index.php/radiologycases/article/view/5288

Peer discussion

Discuss this manuscript in our protected discussion forum at:

www.radiopolis.com/forums/JRCR

Interactivity

This publication is available as an interactive article with scroll, window/level, magnify and more features.

Available online at www.RadiologyCases.com

Published by EduRad



www.EduRad.org