

Gastric infarction following gastric bypass surgery

Patrick H Do^{1*}, Young S Kang¹, Peter Cahill²

1. Department of Radiology, Santa Clara Valley Medical Center, San Jose, USA

2. Department of Surgery, Santa Clara Valley Medical Center, San Jose, USA

* Correspondence: Patrick H Do, Santa Clara Valley Medical Center, Department of Radiology, 751 S. Bascom Ave, San Jose, CA, 95128, USA

(✉ patrickdo@gmail.com)

Radiology Case. 2016 Apr; 10(4):16-22 :: DOI: 10.3941/jrcr.v10i4.2280

ABSTRACT

Gastric infarction is an extremely rare occurrence owing to the stomach's extensive vascular supply. We report an unusual case of gastric infarction following gastric bypass surgery. We describe the imaging findings and discuss possible causes of this condition.

CASE REPORT

CASE REPORT

A 63 year old female presented to the emergency department (ED) with 2 days of nausea, vomiting, diarrhea, and worsening diffuse abdominal pain. Her medical history included hypertension and diabetes, with surgical history of laparoscopic gastric bypass with retrocolic Roux-en-Y gastrojejunostomy, cholecystectomy, and appendectomy, all performed more than 10 years prior. On physical exam, she appeared very uncomfortable and was diaphoretic and tachypneic. She was afebrile with blood pressure 118/65 and heart rate 76. Initial laboratory values were remarkable for a serum lactate level of 3.0 mg/dL and a white blood cell count of 13,500/mm³. This clinical scenario raised suspicion for common complications of Roux-en-Y bypass procedures, including anastomotic stenosis, distention of the excluded stomach, small bowel obstruction, internal hernia, or ulceration.

Initial abdominal radiographs demonstrated gas throughout the small bowel and colon, without free intraperitoneal air (Figure 1). Stomach clips were noted, consistent with prior surgery. Subsequent left lateral decubitus abdominal radiograph demonstrated multiple dilated loops of small bowel with air-fluid levels. Overall these findings were consistent with small bowel obstruction.

A contrast-enhanced computed tomography (CT) scan of the abdomen and pelvis was then performed, again showing multiple dilated, fluid-filled loops of bowel (Figure 2). The gastric remnant was markedly distended with pneumatosis and mildly decreased wall enhancement along the greater curvature. A moderate amount of perigastric fluid was present. There was no significant gastric wall thickening. The visualized portion of the anastomosis of the gastric pouch with the jejunal Roux limb appeared grossly unremarkable. The jejunojejunal anastomosis appeared intact without evidence of dehiscence or leak. There was moderate atherosclerosis at the celiac axis and the superior mesenteric artery, though these vessels were patent.

The patient was then rushed to the operating room for exploratory laparotomy. At surgery, no perforation of bowel was identified, however the patient was found to have a grossly necrotic stomach and purulent fluid within her abdomen. The stomach perforated upon retraction, thus spilling intragastric contents. Irrigation of the peritoneal cavity, ligation of the short gastric arteries, subtotal gastrectomy, small bowel resection, and revision of the Roux-en-Y gastrojejunostomy were performed. During the procedure, the patient's blood pressure dropped to as low as 76/48, though she recovered with transfusion of 2 units of packed red blood cells.

Pathological findings included transmural necrosis of the stomach wall with some submucosal hemorrhage. Abscess and mixed bacteria were found within the fibrinous exudate and necrotic tissue. Near-complete gastric outlet obstruction was noted from the stomach into the duodenum.

On post-operative day 3, the patient returned to the operating room for additional intraperitoneal washout. She was discharged to home in stable condition following a 30 day stay in the intensive care unit.

DISCUSSION

Etiology & Demographics:

Gastric infarction, although frequently fatal, is an extremely rare condition owing to the stomach's rich blood supply from the left and right gastric arteries, the left and right gastroepiploic arteries, as well as the short gastric arteries [1-2].

Only a small number of cases have been reported in the literature, ranging from partial to total infarction, with a variety of etiologies including gastric outlet obstruction, acute gastric dilatation, caustic ingestion, psychogenic polyphagia, atheromatous celiac artery emboli, and therapeutic embolization [3-8]. Though the sample size is small, this entity has been found predominantly in males (3:1 ratio), aged 60 or older.

Prior history of a gastric bypass procedure has not been reported as a risk factor for gastric infarction and a possible association remains unclear.

Clinical & Imaging Findings:

Following a Roux-en-Y bypass operation, common complications seen on CT include anastomotic leak or stenosis, distention of the excluded stomach, staple dehiscence, small bowel obstruction, hernias, marginal ulcers, and also splenic and liver infarction [9-14].

Radiographic findings of gastric infarction include gastric pneumatosis, free intraperitoneal air, and portal venous gas. Additional findings, though non-specific, may include dilated small bowel loops with air-fluid levels and gastric distention.

CT findings of gastric infarction include mucosal hypoenhancement and perigastric fluid in addition to the above radiographic findings, with better anatomic delineation. CT substantially improves sensitivity and utility in pre-surgical planning.

In our patient, jejunojejunal anastomotic stenosis may have led to distention of the gastric remnant, which in turn may have led to gastric infarction. This process, known as a Type B jejunojejunal anastomotic obstruction, is considered a closed loop obstruction, and requires surgical intervention [12]. Manipulation of gastric vasculature may also have played an important role. Indeed, during these surgical operations, short gastric vessels and occasionally branches of the left gastric

artery are routinely ligated, possibly causing vascular compromise to the remaining stomach pouch [15].

Other cases of gastric infarction may be due to venous insufficiency, with or without antecedent acute gastric dilation of any cause, wherein the gastric luminal pressure exceeds gastric venous pressure, causing gastric ischemia [16]. Additional imaging findings may include portal venous air and pneumoperitoneum.

It is important for the radiologist to be aware of, and sensitive to, gastrointestinal (GI) tract complications following a Roux-en-Y gastric bypass procedure. Since post-operative anatomy can make interpretation difficult, it is imperative for the radiologist to be able to identify the gastric pouch, gastric remnant, the gastrojejunal anastomosis and the jejunal Roux limb, and the jejunojejunal anastomosis and the biliopancreatic limb. This case illustrates a hitherto unreported complication where gastric infarction and necrosis were manifested by the presence of pneumatosis and dilatation of the gastric pouch.

Treatment & Prognosis:

Gastric infarction carries a very poor prognosis, with a mortality rate up to 80% if treatment is delayed; thus emergent exploratory laparotomy is necessary [17].

Differential Diagnoses:

The radiologic finding of gastric pneumatosis can be caused by gastric emphysema or emphysematous gastritis. These two entities are distinguished primarily by their clinical contexts. Gastric emphysema is related to a much more benign clinical course, and can be caused by instrumentation, increased intraluminal pressure, air dissection from pneumomediastinum or pneumothorax, or less commonly pneumatosis cystoides [18]. Emphysematous gastritis has a much more dire prognosis, with often similar imaging findings. The pneumatosis is caused by gas-forming organisms within the submucosal layer. Gas may be seen tracking into the portal veins.

Acute gastric dilatation may also present with a massively dilated stomach with mucosal hypoenhancement and pneumoperitoneum, though pneumatosis is not present. A perforated gastric or duodenal ulcer likewise could cause pneumoperitoneum and mimic pneumatosis near the ulcer crater, though wall thickening and irregularity should be identified at this site, rather than diffuse gastric pneumatosis.

Acute gastritis presents on CT with submucosal hypoenhancement, but in this condition the gastric walls and folds are significantly thickened.

Gastric tumors including gastrointestinal stromal tumor (GIST), gastric adenocarcinoma, and gastric lymphoma can be identified by focal or diffuse mass lesions, often with lymphadenopathy.

In conclusion, we demonstrate an unusual case of gastric infarction, which has not previously been described in the setting of Roux-en-Y gastric bypass. Ligation of gastric arterial supply during the bypass operation and post-operative

jejunojejunal anastomotic obstruction may have played significant roles in the development of this condition.

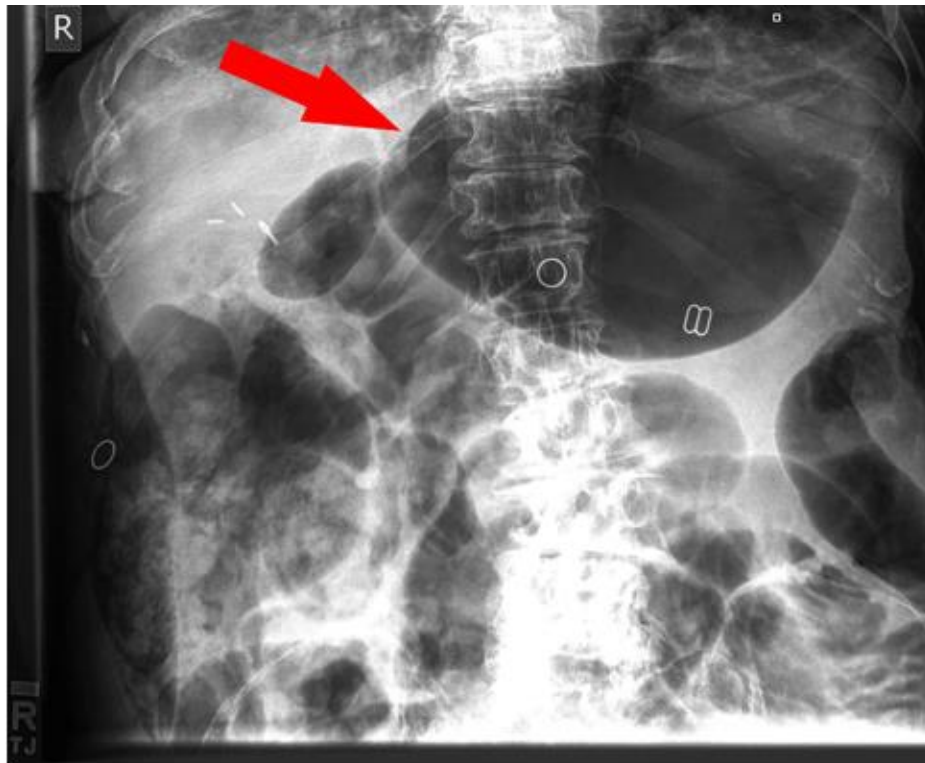
TEACHING POINT

Gastric infarction, though quite rare, is a potential complication of gastric bypass surgery. It is imperative for the radiologist to be aware of, and sensitive to, gastrointestinal (GI) tract complications following a Roux-en-Y gastric bypass. The diagnosis can be made on CT by signs such as gastric pneumatosis and mucosal hypoenhancement. Gastric infarction carries significant mortality risk and requires emergent exploratory laparotomy.

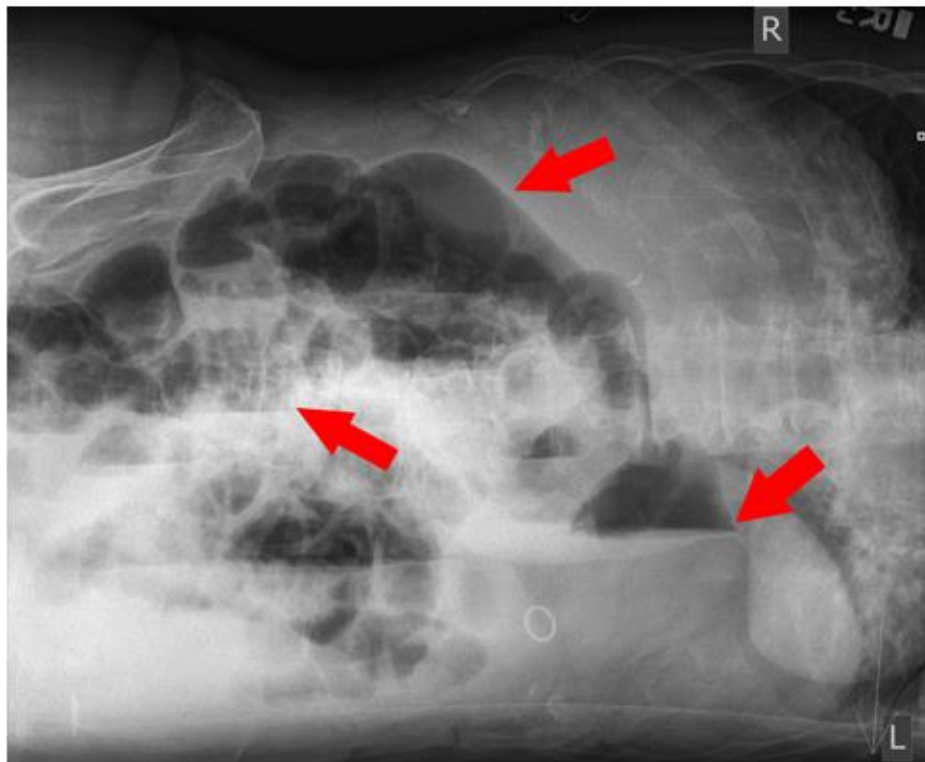
REFERENCES

1. Brown JR, Derr JWM. Arterial Blood Supply of Human Stomach. *AMA Arch Surg* 1952; 64(5): 616-621. PMID: 14923082.
2. Walker TG. Mesenteric Vasculature and Collateral Pathways. *Semin Intervent Radiol* 2009; 26: 167-174. PMID: 21326561.
3. Lin JI, Park YS, Gopalsway N. Gastric Infarction. *Southern Med J* 1991; 84(3): 406-407. PMID: 2000538.
4. Cohen EB. Infarction of the Stomach. Report of three cases of total gastric infarction and one case of partial infarction. *Am J Med* 1951; 11: 645-649. PMID: 14894464.
5. Harvey RI, Doberneck RG, Black WC III. Infarction of the stomach following atheromatous embolization. *Gastroenterology* 1972; 62: 469-472. PMID: 5011536.
6. Bradley EL III, Goldman MI. Gastric infarction after therapeutic embolization. *Surgery* 1976; 79: 421-426. PMID: 1083078.
7. Rodgers JB. Infarction of the gastric remnant following subtotal gastrectomy. *Arch Surg* 1966; 92: 917-921. PMID: 5933260.
8. Saul SH, Dekker A, Watson CG. Acute gastric dilatation with infarction and perforation. *Gut* 1981; 22: 978-983. PMID: 7308853.
9. Andrés M, Pérez M, Roldán J et al. Roux-en-Y gastric bypass: major complications. *Abdominal Imaging* 2007; 32: 613-618. PMID: 17874266.
10. Yu J, Turner MA, Cho S et al. Normal anatomy and complications after gastric bypass surgery: helical CT findings. *Radiology* 2004; 231: 753-760. PMID: 15163816.
11. Blachar A, Federle MP. Gastrointestinal Complications of Laparoscopic Roux-en-Y Gastric Bypass Surgery in Patients Who Are Morbidly Obese. *AJR* 2002; 179: 1437-1442. PMID: 12438032.
12. Levine MS, Carucci LR. Imaging of Bariatric Surgery. *Radiology* 2014; 270: 327-341. PMID: 24471382.
13. Chandler RC, Srinivas G, Chintapalli KN, Schwesinger WH, Prasad SR. Imaging in Bariatric Surgery: A Guide to Postsurgical Anatomy and Common Complications. *AJR* 2008; 190: 122-135. PMID: 18094302.
14. Scheirey CD, Scholz FJ, Shah PC, Brams DM, Wong BB, Pedrosa M. Radiology of the Laparoscopic Roux-en-Y Gastric Bypass Procedure: Conceptualization and Precise Interpretation of Results. *RadioGraphics* 2006; 26: 1355-1371. PMID: 16973769.
15. Maini BS, Blackburn GL, McDermott WV Jr. Technical considerations in a gastric bypass operation for morbid obesity. *Surg Gynecol Obstet* 1977; 145: 907-908. PMID: 929367.
16. Steen S, Lamont J, Petrey L. Acute gastric dilation and ischemia secondary to small bowel obstruction. *Proc (Bayl Univ Med Cent)* 2008; 21(1): 15-17. PMID: 18209748.
17. Koyazounda A, Le Baron JC, Abed N et al. Gastric necrosis from acute gastric dilatation. Recovery after total gastrectomy. *Journal de Chirurgie* 1985; 122 (6-7): 403-407. PMID: 4044701.
18. Pickhardt PJ, Kim DH, Taylor AJ. Asymptomatic pneumatosis at CT colonography: a benign self-limited imaging finding distinct from perforation. *AJR* 2008; 190: W112-117. PMID: 18212192.

FIGURES



A



B

Figure 1: 63 year old female with gastric infarction. (a) Upright frontal abdominal radiograph demonstrates gas throughout the small bowel and colon without free intraperitoneal air. The stomach is markedly dilated, indicated by red arrow. Cholecystectomy clips are noted, consistent with prior surgery. (b) Left lateral decubitus abdominal radiograph demonstrates multiple dilated loops of small bowel with air-fluid levels, consistent with small bowel obstruction, indicated by red arrows. There is no free intraperitoneal air. Cholecystectomy clips are noted, consistent with prior surgery. (GE Proteus XR/a, 70 kVp, 640 mA, 32 mAs, focal spot 1.25)

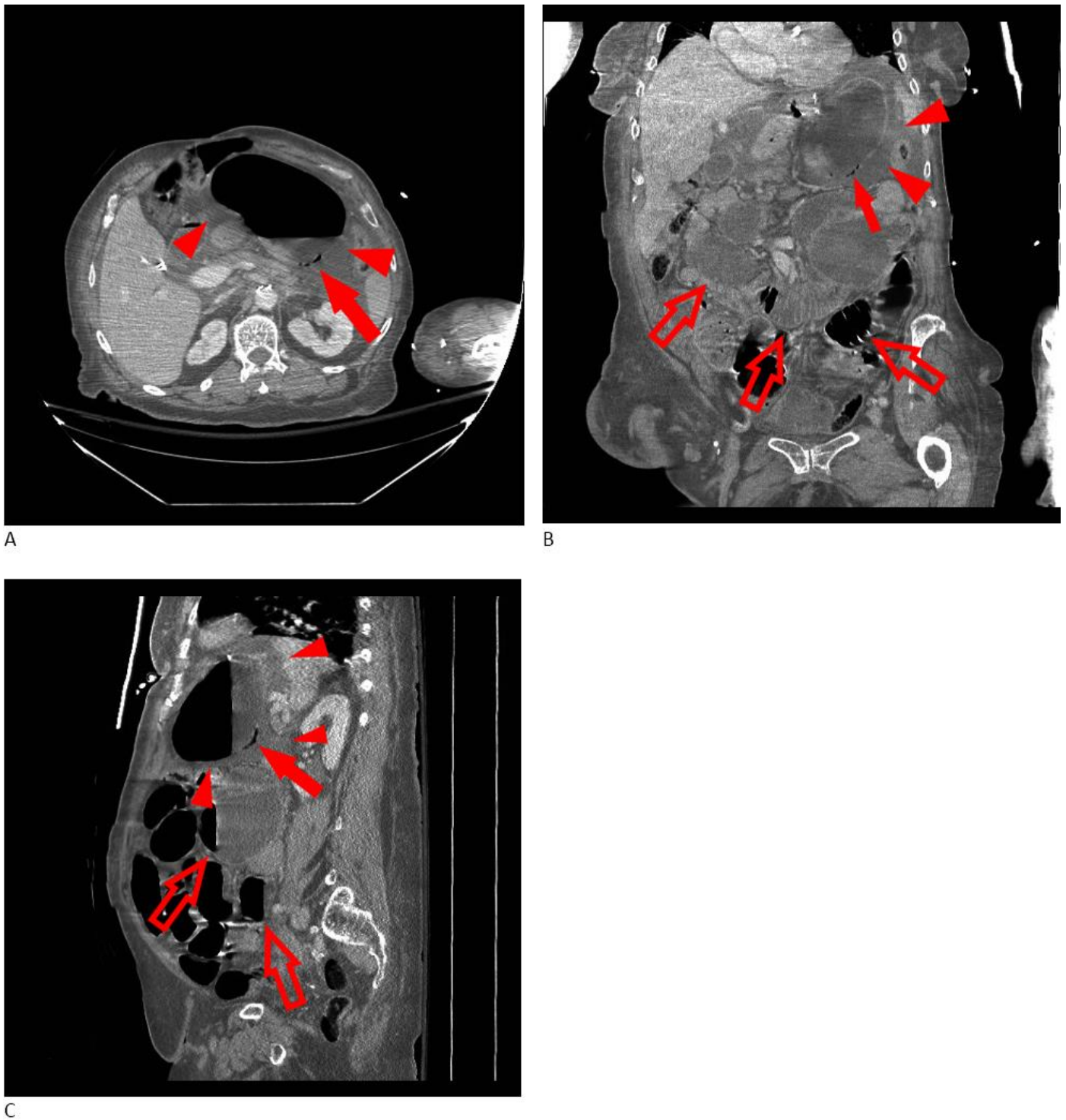


Figure 2: 63 year old female with gastric infarction. (a) Axial contrast-enhanced CT image demonstrates a distended stomach with gastric pneumatosis (red arrow). A moderate amount of perigastric fluid is noted (red arrowheads). (b) Coronal contrast-enhanced CT image demonstrates a distended stomach with gastric pneumatosis (red arrow). Dilated small bowel loops (red open arrows), and a moderate amount of perigastric fluid (red arrowheads) are noted. (c) Sagittal contrast-enhanced CT image demonstrates a distended stomach with gastric pneumatosis (red arrow). Dilated small bowel loops with air-fluid levels (red open arrows) and a moderate amount of perigastric fluid (red arrowheads) are noted. (GE Lightspeed VCT, 120 kVp, 597 mA, 2.5 mm slice thickness, 1.375 pitch, 141 cc Omnipaque 240 IV contrast, portal venous phase)

Entity	Gastric infarction
Etiology	Gastric tissue death caused by interruption of the gastric blood supply.
Incidence	Extremely low. Only 8 cases have been documented in published literature [3-8].
Gender ratio	3:1 male:female [7].
Age predilection	Highest incidence in patients over 60 years old.
Risk factors	Given its rarity, no clear risk factors have been established. Reported cases have occurred with gastric outlet obstruction, acute gastric dilatation, caustic ingestion, psychogenic polyphagia, atheromatous celiac artery emboli, and therapeutic embolization.
Treatment	Emergent exploratory laparotomy.
Prognosis	Very poor prognosis, with mortality rate up to 80% if treatment is delayed.
Imaging findings	<p>Radiography:</p> <ul style="list-style-type: none"> ● free air ● gastric pneumatosis ● portal venous gas <p>CT:</p> <ul style="list-style-type: none"> ● free air ● portal venous gas ● gastric pneumatosis ● perigastric fluid ● distention of the excluded stomach ● distention of the gastric pouch ● mucosal hypoenhancement

Table 1: Summary table of gastric infarction.

Differential diagnoses	Radiography findings	CT findings
Acute gastric dilatation	<ul style="list-style-type: none"> ● massively dilated stomach ● pneumoperitoneum 	<ul style="list-style-type: none"> ● massively dilated stomach ● pneumoperitoneum ● mucosal hypoenhancement
Perforated gastric ulcer	<ul style="list-style-type: none"> ● free air ● ulcer crater, collar, and/or mound on upper GI series 	<ul style="list-style-type: none"> ● wall-thickening, luminal narrowing ● submucosal edema ● free air or enteric contrast, usually at the lesser curvature
Perforated duodenal ulcer	<ul style="list-style-type: none"> ● free air ● persistent ulcer crater or mound on upper GI series, most commonly at the duodenal bulb 	<ul style="list-style-type: none"> ● wall thickening, luminal narrowing ● extraluminal, intraperitoneal, or retroperitoneal gas, usually anterior wall or near bulb
Gastritis	<ul style="list-style-type: none"> ● erosions on upper GI series, varying in location and morphology related to etiology 	<ul style="list-style-type: none"> ● wall thickening and hypoattenuation ● “target” sign of mucosal enhancement and submucosal hypoattenuation ● thickened gastric folds
Gastric gastrointestinal stromal tumor (GIST)	<ul style="list-style-type: none"> ● round, exophytic mass, often with ulceration on upper GI series 	<ul style="list-style-type: none"> ● submucosal, often exophytic mass ● occasionally with gas, fecal material within tumor due to communication with gastric lumen
Gastric adenocarcinoma	<ul style="list-style-type: none"> ● contrast filling defect with irregular, scalloped borders on upper GI series 	<ul style="list-style-type: none"> ● circumferential mucosal mass ● strictures
Gastric lymphoma	<ul style="list-style-type: none"> ● ulcerating masses, thickened gastric folds on upper GI series 	<ul style="list-style-type: none"> ● markedly thickened gastric wall ● regional or widespread lymphadenopathy

Table 2: Differential diagnosis table of gastric infarction.

ABBREVIATIONS

CT = computed tomography
 ED = emergency department
 GI = gastrointestinal
 GIST = gastrointestinal stromal tumor
 ICU = intensive care unit

KEYWORDS

Gastric infarction; Gastric pneumatosis; Acute abdomen; Roux-en-Y gastric bypass; Computed tomography; Stomach diseases

Online access

This publication is online available at:
www.radiologycases.com/index.php/radiologycases/article/view/2280

Peer discussion

Discuss this manuscript in our protected discussion forum at:
www.radiopolis.com/forums/JRCR

Interactivity

This publication is available as an interactive article with scroll, window/level, magnify and more features.
 Available online at www.RadiologyCases.com

Published by EduRad



www.EduRad.org