

# Case report: Portal and systemic venous gas in a patient with perforated duodenal ulcer: CT findings

Maged Nassef Abdalla Fam<sup>1\*</sup>, Khaled Mostafa Elgharib Attia<sup>1</sup>, Safaa Maged Fathelbab Khalil<sup>2</sup>

1. Department of Radiology, Kuwait Hospital, Sharjah, United Arab Emirates

2. Department of Radiology, Ajman Specialty Hospital, Ajman, United Arab Emirates

\* **Correspondence:** Maged Nassef Abdalla Fam, Apartment 707, First Gulf Bank Building, Al Qasimia, Sharjah, P.O Box: 31629-  
Sharjah, United Arab Emirates  
(✉ [maged-fam@hotmail.com](mailto:maged-fam@hotmail.com))

Radiology Case. 2014 Jul; 8(7):20-27 :: DOI: 10.3941/jrcr.v8i7.2070

## ABSTRACT

Gas within the portal circulation has been known to be associated with a number of conditions most commonly mesenteric ischemia and necrosis. Systemic venous gas is described with few conditions and is mostly iatrogenic in nature. We describe a case of combined portal and systemic venous gas detected by computed tomography in a patient with perforated duodenal ulcer.

## CASE REPORT

### CASE REPORT

A 49-years-old male, occasional smoker, non-alcoholic was presented to the emergency department complaining of right para-umbilical pain, which became generalized, and vomiting. There was no history of chronic dyspepsia, heart burn. Past medical history as well as history of drug intake was irrelevant and there was no history of surgical procedures. As a part of the patient's evaluation, an abdominal radiograph (Fig. 1) was done revealing pneumoperitoneum.

The patient was informed that he has to be admitted to our hospital, but he refused and left against medical advice.

Forty eight hours later, the same patient attended the emergency department complaining of worsening abdominal pain, sweating and marked generalized weakness. On examination, the patient was sweating, sick looking and severely dehydrated. Vital signs revealed tachycardia and tachypnea with no fever and normal blood pressure. Proper neurological and chest examinations were unremarkable. His abdomen was distended, with diffuse tenderness and rigidity, his bowel sounds were not audible and per-rectal examination (PR) was negative.

An erect chest radiograph (Fig. 2), again, revealed pneumoperitoneum and immediately a computed tomography (CT) of the abdomen was ordered.

### *Imaging findings*

CT of the abdomen with intravenous (IV) and limited rectal contrast (Fig. 3 & Fig. 4) revealed massive pneumoperitoneum, gas within main portal vein, left portal vein and intrahepatic portal tracts, gas within small mesenteric vessels, gas within IVC, left common iliac vein, anterior division of the right internal iliac vein, both femoral veins and right spermatic veins, air within small bowel wall (intestinal pneumatosis), intraperitoneal free fluid collection, right lower lobe consolidation and right pleural effusion.

### *Management plan*

Decision was made for an emergency laparotomy. Upon exploration, explosive gas was released and a large perforated ulcer, measuring about 3cm in diameter, was found in the first part of duodenum along with severe peritonitis, sloughs of tissues and bowel congestion. Repair of the perforation was done with omental patch. Appendix was inspected and was unremarkable, yet appendectomy was performed.

### *Follow-up*

Postoperatively, the patient was kept ventilated in the intensive care unit (ICU). During his stay in the ICU, patient suffered from surgical wound infection which was treated successfully.

On the 8th day postoperative day, a follow-up CT of the abdomen with oral and IV contrast was done (Fig. 5) and showed resolution of the portal gas, systemic venous gas, pneumoperitonum, intestinal pneumatosis and small bowel dilatation with minimal residual intraperitoneal fluid at the subdiaphragmatic area, some stranding of the peritoneal fat, abdominal wall edema, bilateral pleural effusions and bilateral basal consolidations.

By the 20th postoperative day, the patient was weaned from ventilation and on the 25th day he was transferred from the ICU to the ward. At that time, his wound was clean with unremarkable abdominal signs and bowel motions were satisfactory. The patient was discharged after a while and during his follow-up visit to the outpatient's clinic, he was doing well.

## DISCUSSION

Gas within the portal circulation was first described by Wolfe and Evans in 1955 in six infants who subsequently died from necrotizing enterocolitis (NEC) [1]. The first report of portal venous gas in adults was by Susman and Senturia in 1960 [2]. Afterwards, multiple causes of portal venous gas have been described, these include: arterial and venous mesenteric occlusions, bowel obstruction, perforated gastric ulcers, hemorrhagic pancreatitis, sigmoid diverticulitis, and various iatrogenic causes [3].

Until the late 1980's, portal venous gas was considered as a life threatening sign. However, afterwards there were reports of increasing survival rate in patients having this sign, probably due to iatrogenic causes and increased detection by recent radiological modalities like ultrasound (US) and CT [4].

Mesenteric venous gas is a well known finding in mesenteric ischemia and necrosis. The mesenteric gas can, but not necessarily, progress to reach the portal vein. So, one can find mesenteric venous gas as isolated finding or in conjunction with portal gas [5].

The exact mechanism of occurrence of both portal and mesenteric venous gas is not well understood. Proposed mechanisms include: (1) intestinal wall alteration with disruption or ulceration of the mucosa barrier as in cases of intestinal ischemia, NEC, Crohn's disease, ulcerative colitis, peptic ulcer and iatrogenic causes, (2) Bowel distention allowing intraluminal gas to become intravascular as in post colonoscopy cases, barium enemas, mechanical obstruction and blunt trauma, (3) sepsis occurring with diverticulitis, abdominal abscess, cholangitis, colitis and abdominal tuberculosis. All the previously mentioned mechanisms may lead to mucosal ulceration and excessive gas production by invasive or luminal bacteria [4].

Gas within the systemic circulation is described in cases of decompression sickness, iatrogenic causes, blunt and penetrating abdominal trauma [6]. Systemic venous gas has

been seen with intestinal pneumatosis in a patient with known portal hypertension [7] and in a patient following hemodialysis [8].

To our knowledge, combined portal and systemic venous gas has been described in the literature in six cases [9-13], with no predilection for certain age, sex or race. In the reported cases, the presumed mechanisms for developing gas in both circulations were: fulminant sepsis due to gas forming organisms, necrotizing enterocolitis with a patent ductus venosus, portosystemic shunt in pneumatosis intestinalis, development of systemic venous drainage from the bowel or portosystemic fistula secondary to previous operations, portal obstruction secondary to gas bubbles forced into portal circulation in a case of cystic fibrosis and air entering the epidural veins and reaching the portal circulation through the paravertebral plexus of veins in a patient underwent a lumbar puncture [9-13].

In our patient, who had a delayed presentation and was generally unwell, we presumed that the portal venous gas was due to severe peritonitis and abdominal sepsis which was likely the cause of the intestinal pneumatosis as well.

We also presumed that the systemic venous gas could be due to sepsis. Another theory to explain the systemic venous gas would be that the gas was shifted from the portal side through one of the known portocaval anastomoses, for example superior hemorrhoidal-middle hemorrhoidal veins route, to the systemic side as evidenced by the presence of gas in the internal iliac veins as well as mesenteric veins.

### *Imaging findings and differential diagnoses*

On ultrasound, any intravascular gas can be easily identified in the lumen of the vessel as small mobile echogenic foci or a series of gas bubbles resembling a "string of pearls" moving in the direction of blood flow. Distinguishing gas from other particulate material is not a major concern for experienced medical staff accustomed to US. Gas can be distinguished by its echo characteristics and, in real time, by a velocity greater than that expected for blood within the vessel [6].

Portal venous gas can be diagnosed by plain radiographs, ultrasound and CT. In radiographs it will appear as linear and/or branching lucencies. The CT findings of portal gas is described as branching hypodensities extending to within 2 cm of the liver capsule, predominantly in the anterior-superior aspect of the left lobe [5].

Gas within the intrahepatic biliary channels (pneumobilia) should be differentiated from the gas within the portal tracts. The former being located more at the central portion of the liver owing to the centripetal flow of bile and is not extending as far towards the liver capsule as does portal gas. It usually, therefore, does not extend beyond 2cm from the liver capsule.

Gas in the great mesenteric veins can easily be demonstrated with contrast-enhanced CT while gas in the small mesenteric veins appears as tubular or branched areas of decreased attenuation in the mesenteric border of the bowel.

Mesenteric venous gas should not be confused with pneumoperitoneum [5]. Pneumoperitoneum does not have a tubular or branched appearance and can be found in the interface between the anti-mesenteric border of the bowel and the parietal peritoneum [5].

The systemic venous gas in CT imaging appears as a gas fluid level in axial sections.

#### Treatment and prognosis

The treatment of combined portal and systemic venous gas is directed towards treatment of the cause or the associated condition. Among the reported six cases with this finding, three cases died [9-11]. We believe that more cases should be reported in order to get more realistic statistical data regarding the prognosis in such radiological finding.

#### TEACHING POINT

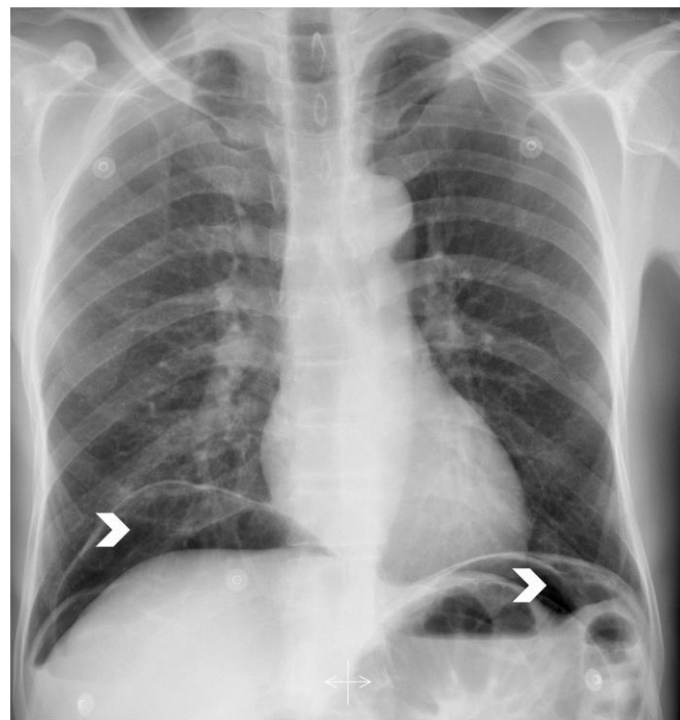
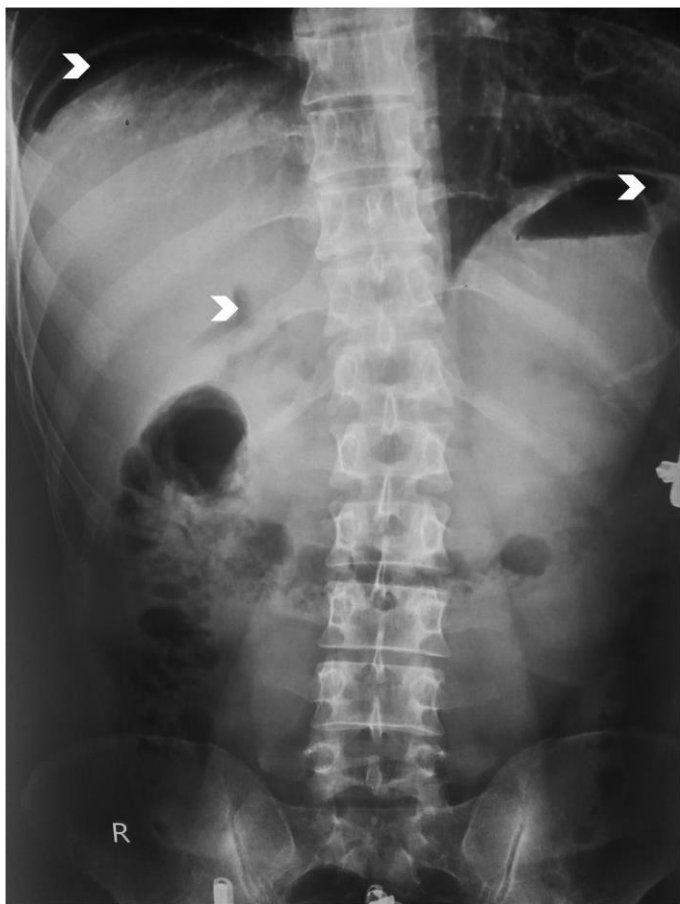Combined portal and systemic venous gas is a rare finding. Identification of portal gas is easily made by computed tomography as branching lucencies extending to within 2 cm of the liver capsule. Gas in the small mesenteric veins appears as tubular or branched areas of decreased attenuation in the mesenteric border of the bowel while systemic venous gas will appear as a gas-fluid level within the vein in axial scans. Until the moment, the exact mechanism of such finding has not been explained.

#### REFERENCES

1. Wolfe JN, Evans WA. Gas in the portal veins of the liver in infants; a roentgenographic demonstration with postmortem anatomical correlation. *Am J Roentgenol Radium Ther Nucl Med.* 1955;74:486-8. PMID: 13249015.
2. Susman N, Senturia HR: Gas embolism of the portal venous system. *AJR* 83:847-850, 1960. PMID:13835795.
3. Griffiths DM, Gough MH: Gas in the hepatic portal veins. *Br J Surg* 73:172-176, 1986. PMID: 3512030.
4. Alqahtani S, Coffin CS, Burak K, Chen F, MacGregor J, Beck P. Hepatic portal venous gas: A report of two cases and a review of the epidemiology, pathogenesis, diagnosis and approach to management. *Can J Gastroenterol.* 2007 May; 21(5): 309-313. PMID: PMC2657713.
5. Sebastià C, Quiroga S, Espin E, Boyé R, Alvarez-Castells A, Armengol M. Portomesenteric vein gas: pathologic mechanisms, CT findings, and prognosis. *Radiographics* 2000;20:1213-1226. PMID:10992012 .
6. Brown MA, Hauschildt JP, Casola G, Gosink BB, Hoyt DB. Intravascular gas as an incidental finding at US after blunt abdominal trauma. *Radiology* 1999 Feb;210(2):405-8. PMID: 10207422.

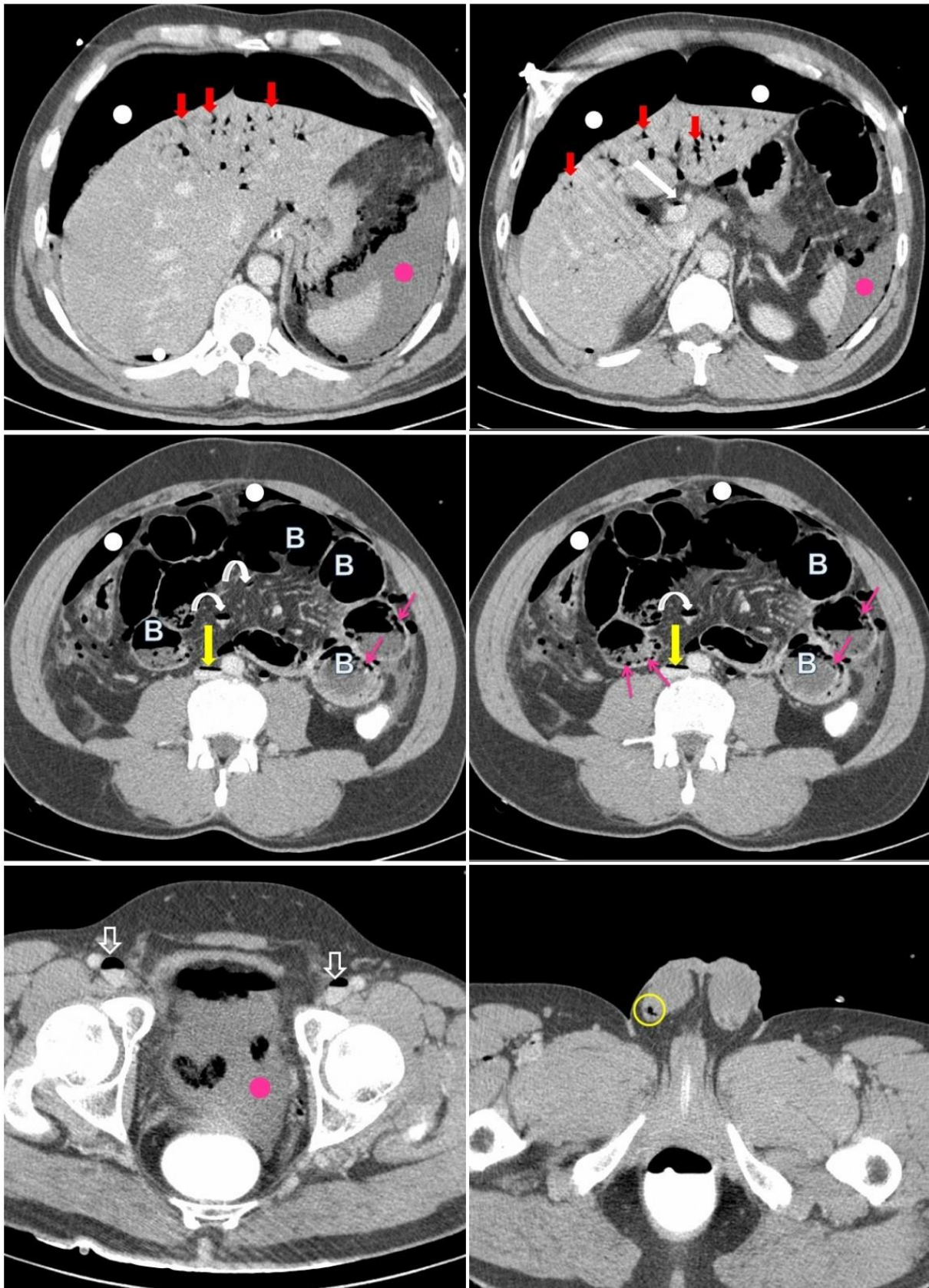
7. Soboleski D, Chait P, Schuckett B, Silberberg P. Sonographic diagnosis of systemic venous gas in a patient with pneumatosis intestinalis. *Pediatr Radiol* 1995; 25:480-481. PMID: 7491209.
8. Rainer N, Poley, Janice Ho, Gretchen A. Gooding. Sonographic Findings of Systemic and Hepatic Venous Gas Associated With Hemodialysis. *J Ultrasound Med* 2009; 28:533-536. PMID: 19321682.
9. Malin SW, Bhutani VK, Ritchie WW, Hall ML, Paul D. Echogenic intravascular and hepatic microbubbles associated with necrotizing enterocolitis. *J Pediatr.* 1983 Oct;103(4):637-40. PMID: 6620027.
10. Jones B. Massive gas embolism in E. coil septicemia. *Gastrointest Radiol* 1981;6:161-163. *AJR Am J Roentgenol.* 1990 Jun;154(6):1219-21. PMID: 7018986.
11. Kriegshauser JS, Reading CC, King BF, Welch TJ. Combined systemic and portal venous gas: sonographic and CT detection in two cases. *AJR Am J Roentgenol.* 1990 Jun;154(6):1219-21. PMID: 2110731.
12. Mallens WM, Schepers-Bok R, Nicolai JJ, Jacobs FA, Heyerman HG. Portal and systemic venous gas in a patient with cystic fibrosis: CT findings. *American Journal of Roentgenology* 1995;165: 338-339. PMID: 7618551.
13. Karaosmanoglu D, Oktar SÖ, Araç M, Erbas G. Portal and systemic venous gas in a patient after lumbar puncture. *British Journal of Radiology* (2005) 78, 767-769. PMID: 16046434.
14. Little AF, Ellis SJ. 'Benign' hepatic portal venous gas. *Australas Radiol.* 2003 Sep; 47(3):309-12. PMID: 12890256.

FIGURES

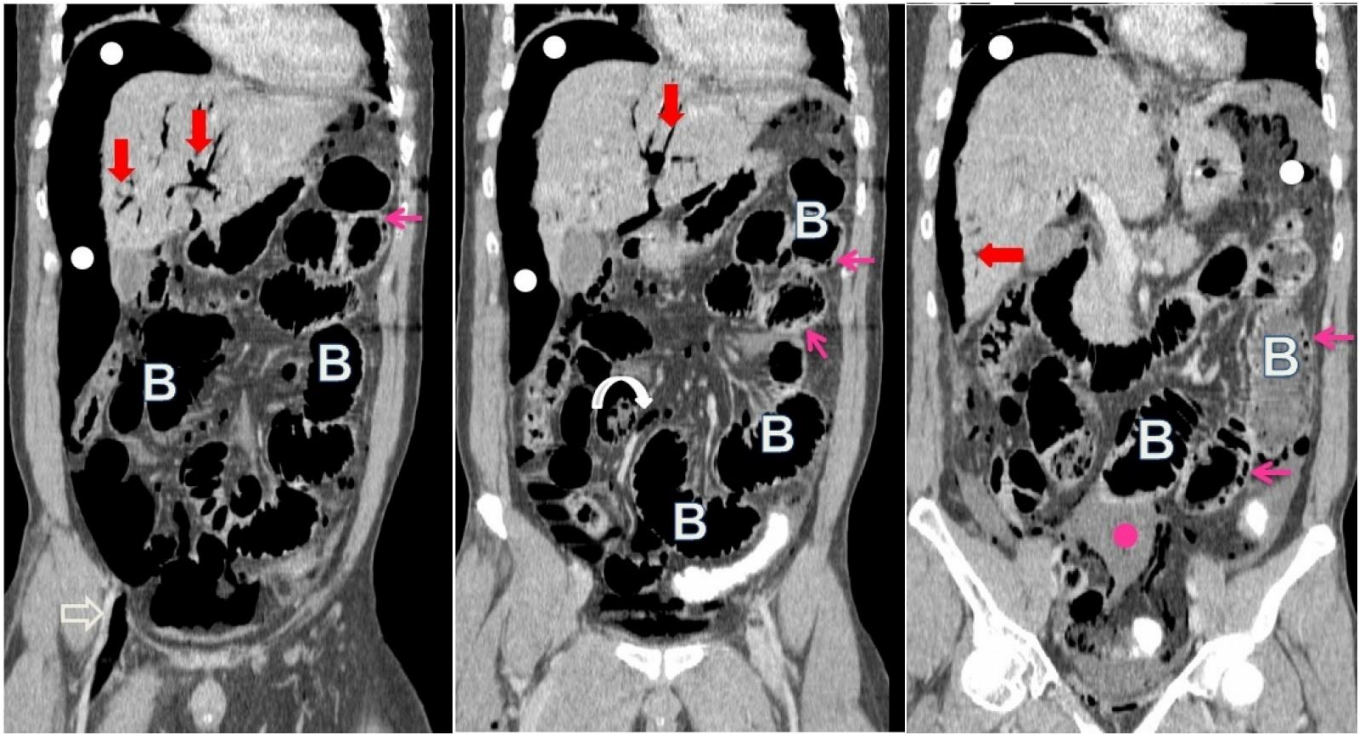


**Figure 2:** Chest radiograph (Erect). 49-years-old man with perforated duodenal ulcer. Findings: lucent areas of free intraperitoneal gas (white arrowheads).

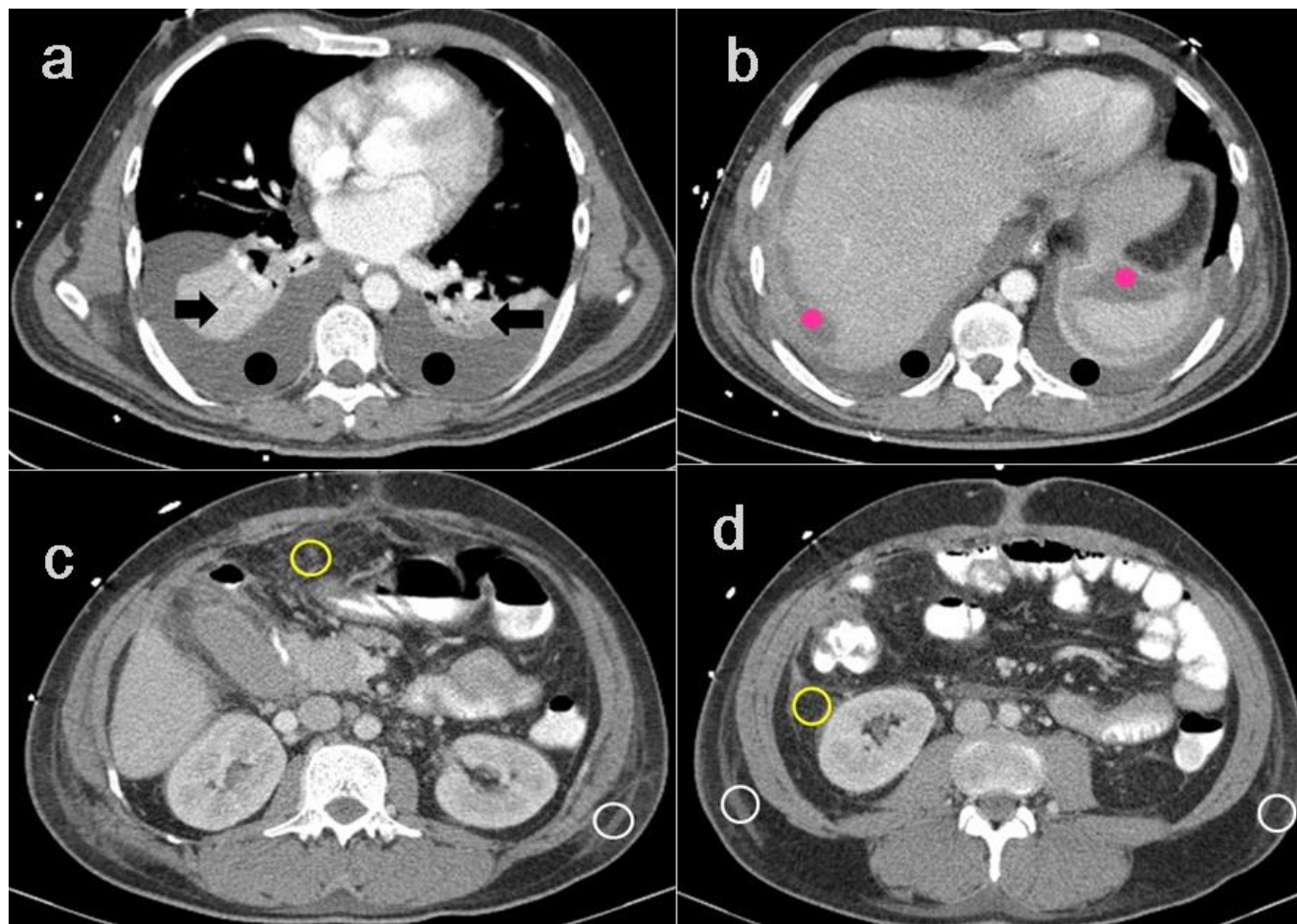
**Figure 1:** Abdominal radiograph (Erect). 49-years-old man with perforated duodenal ulcer. Findings: lucent areas of free intraperitoneal gas (white arrowheads).



**Figure 3:** Computed Tomography. 49-years-old man with perforated duodenal ulcer. Axial CT images with IV and limited rectal contrast (patient evacuated the contrast). Findings: massive pneumoperitoneum throughout the abdominal cavity (white dots), gas within the main portal vein ( long white arrow) , portal venous gas (short red arrows), gas within the small mesenteric vessels (curved white arrows). Gas within systemic veins : IVC (long yellow arrow), both femoral veins (open arrows) , right spermatic veins (yellow open circle). Dilated small bowel (B), air within small bowel wall (pink arrows), intraperitoneal free fluid collection (pink dots) Technique: Scanner: Siemens Somatom emotion , 95 mAs, 130 Kv, slice thickness 2.5mm, intravenous contrast:100 ml Omnipaque 300, rectal contrast: Gastrografin 200ml/in 800ml water.



**Figure 4:** Computed Tomography. 49-years-old man with perforated duodenal ulcer. Coronal reformatted images with IV and limited rectal contrast (patient evacuated the contrast). Findings: pneumoperitoneum throughout the abdominal cavity (white dots), portal venous gas (short red arrows), gas within the small mesenteric vessels (curved white arrow) and right external iliac vein (open arrow). Dilated small bowel (B), air within SB wall (pink arrows), intraperitoneal free fluid collection (pink dots). Technique: Scanner: Siemens Somatom emotion. 95 mAs, 130 Kv, slice thickness 2.5mm, intravenous contrast: 100 ml Omnipaque 300, rectal contrast: Gastrografin 200ml/in 800ml water.



**Figure 5:** Computed Tomography. 49-years-old man with perforated duodenal ulcer. Follow-up scan on the 8th postoperative day. Axial CT images from the same patient with intravenous and oral contrast. Findings: resolution of the portal gas, systemic venous gas, pneumoperitoneum, intestinal pneumatosis and small bowel dilatation. There is minimal residual intraperitoneal fluid at the subdiaphragmatic area (pink dots), some stranding of the peritoneal fat (yellow circle), abdominal wall edema (white circle), bilateral pleural effusions (black dots) and bilateral basal consolidations (black arrow). Technique: Scanner: Somatom emotion . 99 mAs, 130 Kv, slice thickness 2.5mm, intravenous contrast: 100 ml Omnipaque 300, oral contrast: Telebrix 300mg- 200ml in 250ml water.

<b>Etiology</b>	Intestinal ischemia, sepsis, necrotizing enterocolitis, iatrogenic, trauma
<b>Incidence</b>	Six cases reported in published literature
<b>Gender ratio</b>	None
<b>Age predilection</b>	None
<b>Risk factors</b>	Theories include: intestinal wall alteration, bowel distention and sepsis
<b>Treatment</b>	Treatment of the cause
<b>Prognosis</b>	50% mortality among the reported cases
<b>Findings on CT imaging</b>	<ul style="list-style-type: none"> <li>• Portal venous gas is described in CT as branching lucencies extending to within 2 cm of the liver capsule</li> <li>• Gas in the small mesenteric veins appears as tubular or branched areas of decreased attenuation in the mesenteric border of the bowel in CT scans.</li> <li>• Systemic venous gas in axial CT imaging appears as gas fluid level.</li> </ul>

**Table 1:** Summary table for combined portal and systemic venous gas

Differential	CT findings
Portal venous gas	Branching lucencies extending to within 2 cm of the liver capsule
Pneumobilia	Located more at the central portion of the liver, usually does not extend beyond 2cm from the liver capsule
Mesenteric venous gas	Tubular or branched areas of decreased attenuation in the mesenteric border of the bowel
Pneumoperitoneum	Does not have a tubular or branched appearance and can be found in the interface between the antimesenteric border of the bowel and the parietal peritoneum

**Table 2:** Differential diagnosis table for portal and mesenteric venous gas

#### ABBREVIATIONS

CT: Computed Tomography  
ICU: Intensive care unit  
IV: Intravenous  
NEC: Necrotizing Enterocolitis  
PR: per rectal examination  
US: Ultrasound

#### KEYWORDS

Portal gas; venous gas; ischemia; systemic venous gas ;  
computed tomography; perforated; duodenal ulcer

#### Online access

This publication is online available at:  
[www.radiologycases.com/index.php/radiologycases/article/view/2070](http://www.radiologycases.com/index.php/radiologycases/article/view/2070)

#### Peer discussion

Discuss this manuscript in our protected discussion forum at:  
[www.radiolopolis.com/forums/JRCR](http://www.radiolopolis.com/forums/JRCR)

#### Interactivity

This publication is available as an interactive article with  
scroll, window/level, magnify and more features.  
Available online at [www.RadiologyCases.com](http://www.RadiologyCases.com)

Published by EduRad



[www.EduRad.org](http://www.EduRad.org)