

Gastrointestinal amyloidosis presenting as enterocolitis on abdominal CT scan

Inneke Willekens^{1*}, Frederik Vandenbroucke¹, Jacques Sennesael², Johan de Mey¹

1. Department of Radiology, UZ Brussel, Brussels, Belgium

2. Department of Nephrology, UZ Brussel, Brussels, Belgium

* **Correspondence** Inneke Willekens, MD, In vivo Cellular and Molecular Imaging - ICMI - Vrije Universiteit Brussel, Department of Radiology - UZ Brussel, Laarbeeklaan 101, 1090 Brussels, Belgium
(✉ inneke.willekens@gmail.com)

Radiology Case. 2009 Oct; 3(10):11-14 :: DOI: 10.3941/jrcr.v3i10.165

ABSTRACT

The imaging findings of amyloidosis are nonspecific and diverse due to its association with various chronic diseases such as multiple myeloma. We report a case of gastrointestinal amyloidosis presenting as enterocolitis on a contrast enhanced CT scan of the abdomen.

CASE REPORT

CASE REPORT

Introduction

Amyloidosis is a disease often involving the gastrointestinal tract. CT scan can show bowel wall thickening, dilatation, and luminal narrowing in the small intestine and/or colon. Yet the diagnosis of amyloidosis must be supported by histopathological examination as it has no pathognomic radiologic features. In this report, we present a patient with amyloidosis mimicking enterocolitis on CT scan.

Case report

An 81 year old woman was admitted to the emergency department of our hospital with a 2-day history of diffuse colicky abdominal pain associated with nausea and vomiting, followed by diarrhea and hematochezia. She had also been suffering from anorexia, pruritus and edema for a couple of weeks. Past medical history included a cholecystectomy and Kliegel surgery for an inguinal hernia. Physical examination revealed a diffusely tender abdomen without rebound tenderness. The patient had elevated levels of C-reactive protein, white blood cells, creatinine and uric acid. Plain radiograph of the abdomen (Fig. 1) showed some fluid levels in the small intestine. Upper gastrointestinal endoscopy

demonstrated reflux oesophagitis. An IV contrast enhanced (80 cc non-ionic iodinated contrast medium, Ultravist® (iopromide), Bayer HealthCare Pharmaceuticals, Düsseldorf, Germany) multidetector CT scan of the abdomen (Fig. 2) showed wall thickening of several segments of the small intestine with high grade stricture and prestenotic dilatations. There was some free fluid around the liver and in the pelvis. The presence of skip lesions with irregular wall thickening was suggestive of Crohn disease.

Two days after admission her renal function rapidly deteriorated. Renal ultrasound was normal, except for bilateral cysts.

Complementary blood analysis showed elevated Ig-G and positive Anca type P-ANCA levels, raising the possibility of polyarteritis nodosa.

The patient refused further examinations and operations. She died in a palliative setting, 11 days after being admitted to hospital.

Autopsy revealed terminal renal insufficiency due to systemic amyloidosis type AA as result of a diffuse and interstitial multiple myeloma. The systemic amyloidosis involved kidneys, small intestine, colon, lungs, spleen, heart, lymph nodes, thyroid and bone marrow. The lungs showed cylindrical bronchiectasies. There was also microscopic

polyangiitis with ANCA related necrotising glomerulonephritis and signs of vasculitis in liver, heart, subcutaneous fat and beginning necrosis of the small intestine with signs of vasculitis and a cholesterol emboli. No signs of polyarteritis nodosa or Crohn disease were found at autopsy.

DISCUSSION

Amyloidosis is defined as an extracellular deposit of protein fibrils with a β -sheet fibrillar structure (1). Reactive or secondary amyloid A amyloidosis (AA) is caused by the accumulation of acute-phase reactant serum amyloid A (SAA) protein (2). The expression of the fibril in the liver is under the control of interleukin (IL)-1, IL-6 and tumor necrosis factor (TNF)-alpha (3). AA amyloidosis may develop in patients with chronic rheumatic diseases, longlasting infections, hereditary periodic syndromes, and non-specific bowel diseases (4). Another type of amyloidosis is primary immunoglobulin light chain amyloidosis (AL) which is associated with plasma cell dyscrasia. Gastrointestinal involvement is most common in AL amyloidosis. Fifteen percent of patients with AL have multiple myeloma (2). Rheumatoid arthritis is found in 48% of such patients (6). Beta-2 microglobulin protein fragments are not cleared by dialysis and lead to hemodialysis-associated amyloidosis (HAA) (5). This disease usually occurs after 15 years of dialysis (7). Prealbumin (transthyretin)-derived amyloidosis (TTR) is a hereditary disease caused by a mutation in a prealbumin gene (5). Senile amyloidosis is seen in patients over 80 years old and involves the heart, but can also be seen in the GI tract (8). Local amyloidosis is found in the esophagus, stomach, small intestine and colon (2).

The incidence of systemic amyloidosis involving the gastrointestinal tract is 98% (9).

Abdominal CT scan in patients with amyloidosis of the alimentary tract can show normal bowel findings. When abnormal findings are present, GI wall thickening and/or bowel wall dilatation without wall thickening may be seen. Bowel wall thickening on CT scan correlates with submucosal and interstitial distribution of the disease. Soft tissue infiltration and adenopathies are occasionally noted (5).

The small intestine is the most common site of involvement in the gastrointestinal tract (10). When the small intestine is involved, symptoms such as abdominal pain, diarrhea, hemorrhage, obstruction, and malnutrition can be present (11). Often there is an impaired motility (12). The most common radiological finding in barium studies is a symmetrical thickening of the folds, which represents edema caused by ischemia due to vascular deposition of amyloid. Other findings are jejunalization of the ileum, impaired motor activity, small polypoid protrusions, fine granular densities, and amyloid tumors. CT findings of small intestinal involvement include bowel wall thickening, dilatation, and mesenteric infiltration (10). Also intussusception is described (12).

When the colon is affected, the descending and rectosigmoid colon are mostly involved (13). The clinical symptoms vary from diarrhea and rectal bleeding to intestinal

pseudo-obstruction or signs of acute abdomen (14). Barium enema shows luminal narrowing, loss of colonic haustrations, thickened mucosal folds, and a nodular mucosal pattern (13). CT findings include thickening of the colonic wall, luminal narrowing and distention, and a perforated giant diverticulum (13,14). CT scan cannot reliably differentiate amyloid infestation from other causes of ischemic colitis or inflammatory bowel disease (12).

In AA amyloidosis, as in the presented case, a coarse mucosal pattern with innumerable fine granular elevations is correlated with amyloid deposits in the lamina propria. In the small intestine, the most common abnormality is the symmetric thickening of the valvulae conniventes (15).

The CT image of amyloidosis resembles that of an inflammatory or ischemic enterocolitis. The wall is thickened, its lumen is narrowed and intussusception may be present. Irregular plicae thickening can be seen as well. The diagnosis of amyloidosis must be supported by histopathological examination as it has no pathognomic radiologic picture (8).

TEACHING POINT

Gastrointestinal amyloidosis has aspecific imaging findings. When the presence of amyloidosis on a contrast enhanced CT scan of the abdomen is likely, a biopsy has to be obtained to confirm the diagnosis histopathologically.

REFERENCES

1. Asaumi J, Yanagi Y, Hisatomi M, et al. CT and MR imaging of localized amyloidosis. *Eur J Radiol* 2001;39(2):83-87
2. Ebert EC, Nagar M. Gastrointestinal manifestations of amyloidosis. *Am J Gastroenterol* 2008 ;103 :776-787
3. Westermarck P, Westermarck PT. Reflections on amyloidosis in Papua New Guinea. *Phil Trans R Soc B* 2008;363:3701-3705
4. Potyřová Z, Merta M, Tesar V, et al. Renal AA amyloidosis: survey of epidemiologic and laboratory data from one nephrologic centre. *Int Urol Nephrol* 2009 Jan 31.
5. Araoz PA, Batts KP, MacCarty RL. Amyloidosis of the alimentary canal: radiologic-pathologic correlation of CT findings. *Abdom Imaging* 2000;25:38-44
6. Gertz MA, Kyle RA. Secondary systemic amyloidosis: Response and survival in 64 patients. *Medicine* 1991;70:246-256
7. Dulgheru EC, Balos LL, Baer AN. Gastrointestinal complications of β 2-microglobulin amyloidosis: A case report and review of the literature. *Arthritis Rheum* 2005;53:142-145

8. Rocken C, Saeger W, Linke RP. Gastrointestinal amyloid deposits in old age. Report on 110 consecutive autopsical patients and 98 retrospective bioptic specimens. *Pathol Res Pract* 1994;190:641-649

9. Kuang L, Sun W, Gibson MF, et al. Gastrointestinal amyloidosis with ulceration, hemorrhage, small bowel diverticula, and perforation. *Dig Dis Sci* 2003;48(10):2023-2026

10. Tada S, Iida M, Matsui T, et al. Amyloidosis of the small intestine : findings on double-contrast radiographs. *AJR* 1991;156:741-744

11. Kim SH, Han JK, Lee KH, et al. Abdominal amyloidosis: Spectrum of radiological findings. *Clin Radiol* 2003;58:610-620

12. Urban BA, Fishman EK, Goldman SM, et al. CT evaluation of amyloidosis: Spectrum of disease. *RadioGraphics* 1993;13:1295-1308

13. Trinh TD, Jones B, Fishman EK. Amyloidosis of the colon presenting as ischemic colitis: a case report and review of the literature. *Gastrointest Radiol* 1991;16:133-136

14. Diaz Candamio MJ, Pombo F, Yebra MT. Amyloidosis presenting as a perforated giant colonic diverticulum. *Eur Radiol* 1999;9:715-718

15. Tada S, Iida M, Yao T, et al. Gastrointestinal amyloidosis: Radiologic features by chemical types. *Radiology* 1994;190:37-42

16. Kala Z, Valek V, Kysela P. Amyloidosis of the small intestine. *Eur J Radiol* 2007;63:105-109

FIGURES

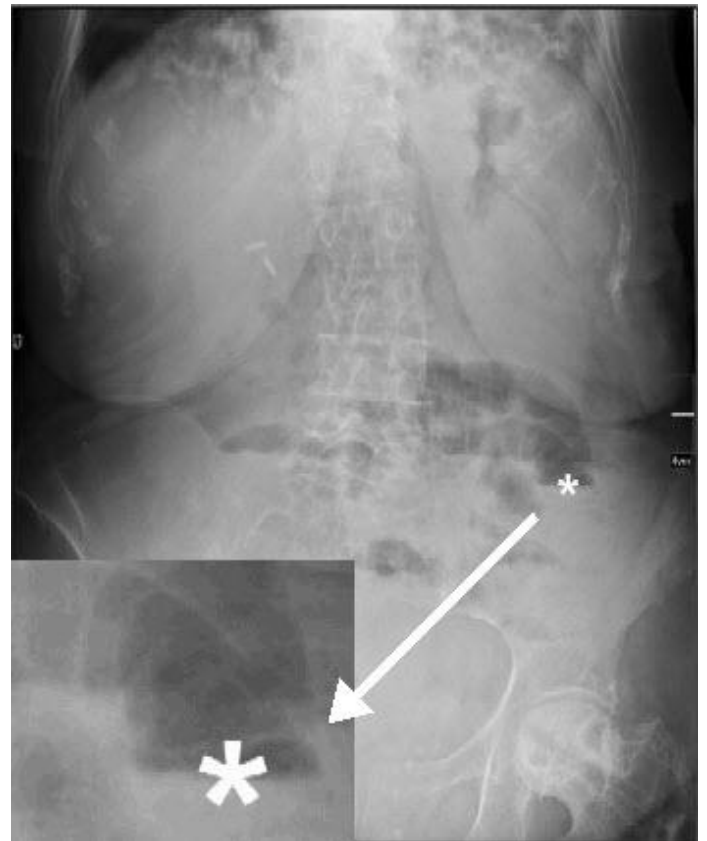


Figure 1: 81 year old woman with gastrointestinal amyloidosis presenting as enterocolitis on abdominal CT scan. The upright plain radiograph of the abdomen reveals some fluid levels in the small intestine (asterisk). Surgical clips post gall bladder removal.

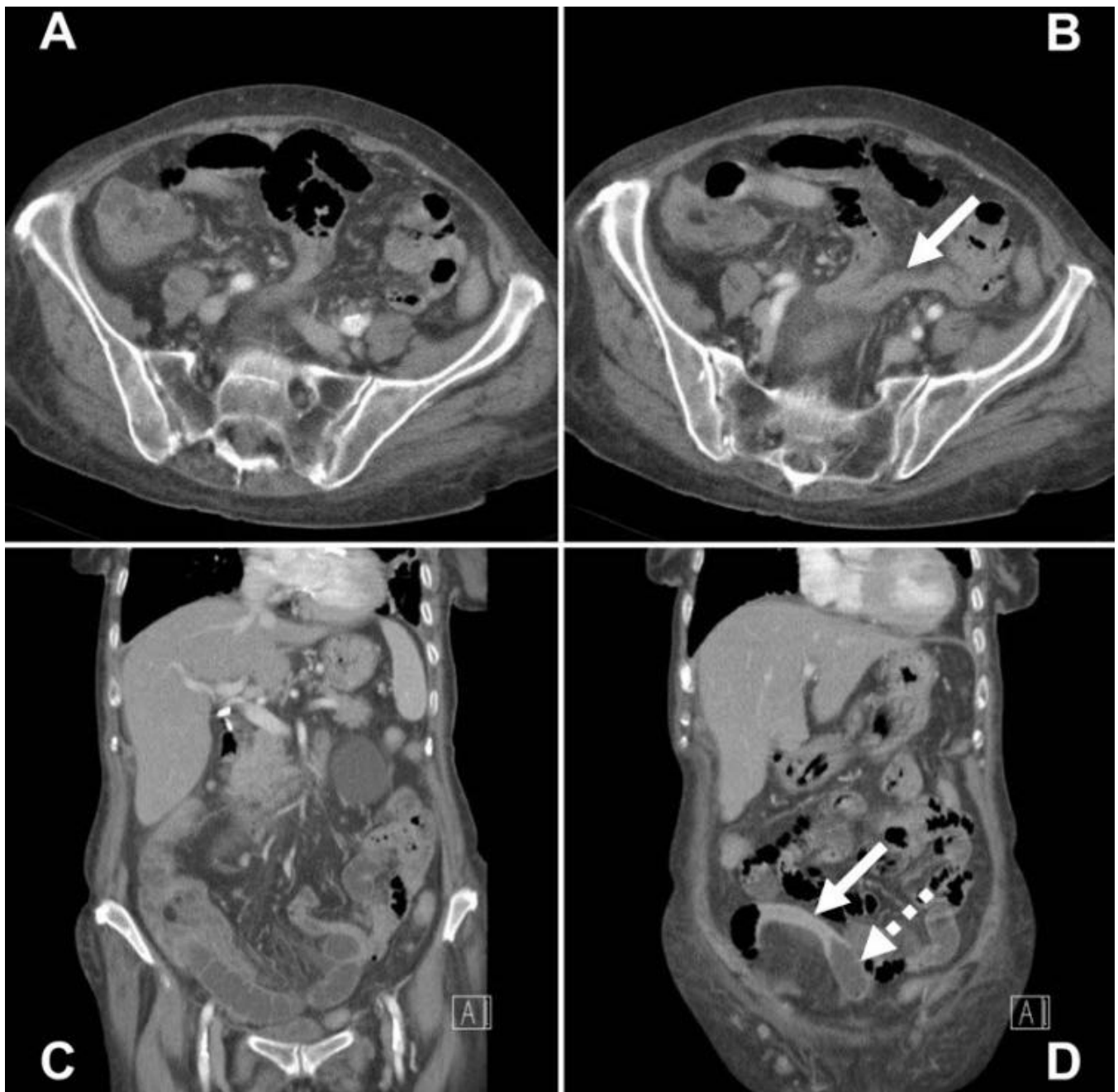

Figure 2: 81 year old woman with gastrointestinal amyloidosis presenting as enterocolitis on abdominal CT scan. Axial (A and B) and coronal (C and D) multiplanar reformatted computed tomography images show wall thickening of several segments of the small intestine (arrow in B) with high grade stricture (arrow in D) and prestenotic dilations (dotted arrow in D).

Journal of Radiology Case Reports

www.RadiologyCases.com

ABBREVIATIONS

- CT = computed tomography
- Ig-G - immunoglobulin G
- Anca = antineutrophil cytoplasmic antibodies
- P-ANCA = perinuclear-staining antineutrophil cytoplasmic antibodies
- AL = amyloid light chain amyloidosis
- AA = amyloid A amyloidosis
- HAA = hemodialysis-associated amyloidosis
- TTR = transthyretin-derived amyloidosis

KEYWORDS

Amyloidosis, Gastrointestinal, CT

Online access

This publication is online available at:
www.radiologycases.com/index.php/radiologycases/article/view/165

Interactivity

This publication is available as an interactive article with scroll, window/level, magnify and more features.
 Available online at www.RadiologyCases.com

Published by EduRad



www.EduRad.org